

CASE REPORT

OPEN ACCESS

Full open access to this and thousands of other papers at <http://www.la-press.com>.

Spontaneous Collapse of Bilateral Bullae with Conservative Management

Masood A Shariff¹, Vijay A Singh¹, Edward D Daniele¹, Nikhil Goyal², Deliana Peykova¹, John P Nabagiez¹ and Frank M Rosell¹

¹Department of Cardiothoracic Surgery, Staten Island University Hospital, 475 Seaview Ave, Staten Island, New York 10305. ²Department of Radiology, Staten Island University Hospital, 475 Seaview Ave, Staten Island, New York 10305. Corresponding authors email: mshariff@siuh.edu

Abstract: We report a case of bilateral apical lung bullae that collapsed following an episode of community-acquired pneumonia with bilateral air fluid levels. With standard treatment for community-acquired pneumonia, management of a patient that may have qualified for bullectomy, (as in our case) showed complete resolution of all pathology without surgical intervention. Conservative management took precedence in alleviating pathology over surgical intervention.

Keywords: emphysema/bullae, lung infection, infection, chest

Clinical Medicine Insights: Case Reports 2013:6 107–111

doi: [10.4137/CCRep.S11187](https://doi.org/10.4137/CCRep.S11187)

This article is available from <http://www.la-press.com>.

© the author(s), publisher and licensee Libertas Academica Ltd.

This is an open access article published under the Creative Commons CC-BY-NC 3.0 license.

Introduction

An air space in the lung measuring more than 1 centimeter in diameter is defined as a bulla, which consists of nonventilated air pockets formed by compressed and attenuated lung tissue.^{1,2} This entity is highly associated with emphysema, which is most commonly caused by smoking. Air fluid levels inside bullae are an unusual complication of chronic obstructive pulmonary disease and the therapeutic antibiotics or bronchoscopy have not been evaluated.³ Giant bullous emphysema, occupying large portions of the hemithorax, can be treated with bullectomy when lung-function is affected and improvement has been seen in the intermediate and long-term follow up.^{2,4-7} Localized bullae have shown better results with bullectomy as oppose to medical management.⁸ Few reports have shown spontaneous collapse of bullae in long term follow-up.^{3,9} In our report, we present a case that highlights a unique aspect of conservative antibiotic therapy for a community-acquired pneumonia-related infectious process that voided the need for surgical intervention.

Case Report

In September 2009, a 49-year-old African-American man presented with shortness of breath, non-productive cough, and a fever of 1-week duration. He had seen his primary care doctor 1 week prior for similar symptoms and was prescribed antibiotics for a suspected infectious process.

His medical history was significant for coronary artery disease, peripheral vascular disease, hypertension, hypercholesterolemia, sleep apnea, and history of bilateral apical bullae. He had a surgical history of disk herniation surgery and percutaneous coronary intervention for right femoral stent. He had a 22 pack-year smoking history, but had quit using tobacco products 20 years before and denied any alcohol or narcotic use. The patient has been following up with his pulmonologist for the bilateral apical bullae. A chest x-ray (CXR) taken in November 2006 (Fig. 1A) showed hyperinflated lungs with bilateral upper lobe bullae, which was again seen by computed tomography on admission (Fig. 1B).

At admission in 2010, the CXR and the CT-scan showed upper lobe bullae with air fluid levels in the left upper lobe with a small left plural effusion. The CXR showed bilateral bullae, with an air fluid level

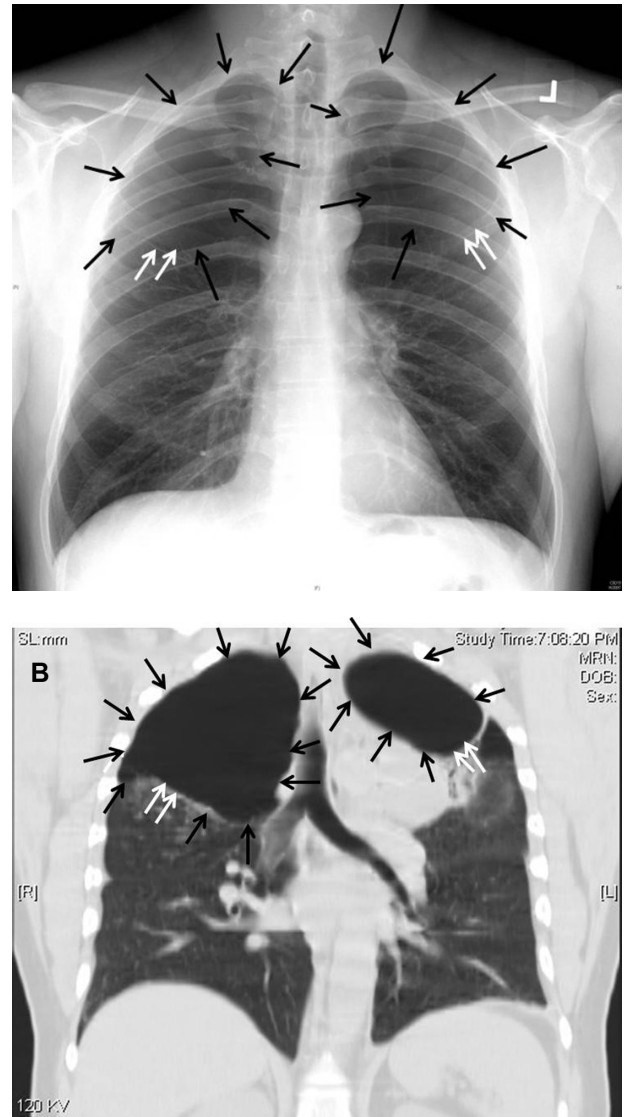


Figure 1. (A) Chest radiograph prior to admission showing hyperinflated lungs, biapical bullous disease as evidenced by lucency without lung markings (black arrows). Note inferior border of bullae is seen (double white arrows). (B) Computer tomography at admission with coronal reformatted images confirms the bullous disease (black arrows); inferior border of bullae (double white arrows).

on the left side (Fig. 2A), and the CT-scan of the chest confirmed multiple bilateral upper lobe bullae with air fluid levels in the left upper lobe bullae. The Infectious Disease department was consulted on the case and ceftriaxone, azithromycin, and clindamycin were started for the presumed diagnosis of pneumonia. Upon feeling better, he was discharged on 2 g ceftriaxone IV piggyback once a day for 3 more weeks (he was already on it for 9 days previously) and clindamycin, 450 mg, every 8 hours. A Pulmonology consult was also called, and it was suggested that

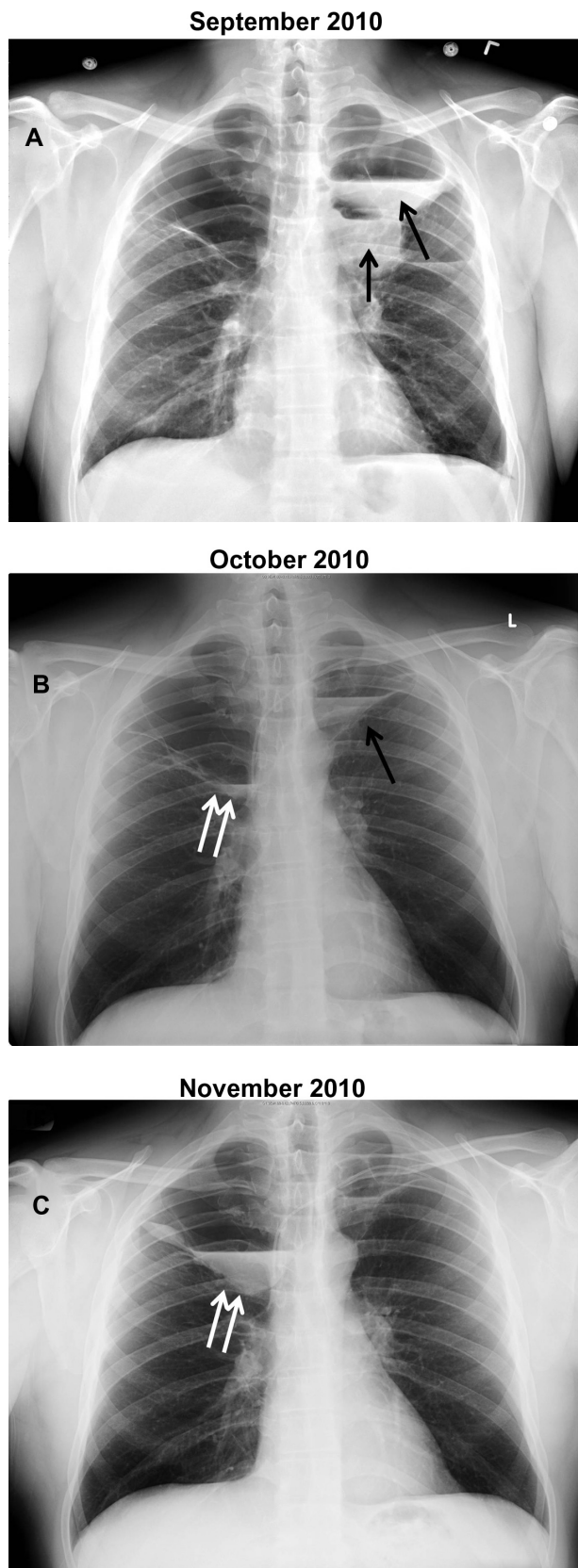


Figure 2. Serial chest radiographs showing (A) air fluid levels in left upper lobe bullae (black arrows). Over the course of 3 months the left upper lobe bullae air fluid level decreases with concurrent development of new air fluid level with in right apical bullae (double white arrow) (B and C).

the patient had infected bullae, with possible community acquired pneumonia. For teaching purposes, several tests were completed. Alpha-1 antitrypsin levels were 232 (normal range: 83–199 mg/dL) and alpha-1-antitrypsin deficiency phenotype test confirmed no mutations; these tests ruled out any suspicion of emphysema. His blood cultures were negative. His physicians had a presumptive diagnosis of community-acquired pneumonia for which he would be treated with a prolonged course of antibiotics.

The patient was discharged on hospital day 9 with clindamycin and ceftriaxone for 3 more weeks. He was also encouraged to consult with cardiothoracic surgery for evaluation of the possibility for bullectomy, in order to limit future complications of infection or pneumothorax. A follow-up chest x-ray 2 weeks after discharge revealed bilateral bullae with air fluid levels on the left and a new air fluid level on the right (Fig. 2B). During his time at home, the patient was still complaining of shortness of breath and cough. Given this information, he was still not a candidate for any type of surgical intervention, but the antibiotics course was continued. 6 weeks after the patient was discharged, the chest x-ray showed a resolution of the left apical air-fluid level and an expansion of the right sided bullae, with a larger air fluid level (Fig. 2C). The patient continued to complain of sporadic symptoms; therefore, his antibiotic course was continued.

At 4-month follow-up, the patient's symptoms were completely resolved. A chest x-ray revealed a complete resolution of all air fluid levels and bullae (Fig. 3A), confirmed by CT-scan (Fig. 3B). A long-term follow-up CT-scan at 16 months (July 2012) revealed no change in the radiographic findings from the CT-scan done at the 4-month follow up appointment (Fig. 4). At that point, the patient was asymptomatic with no identifiable radiographic pathology and did not qualify for surgical intervention. The patient had complete clearance of symptoms and radiographic pathology, managed solely with antibiotics.

Discussion

Antibiotic treatment was initiated after the patient clinically developed pneumonia with evidence of air fluid levels on chest x-ray. A thorough work-up was performed showing no evidence of lung abscess or empyema as evidenced by CT-scan (Fig. 1B).

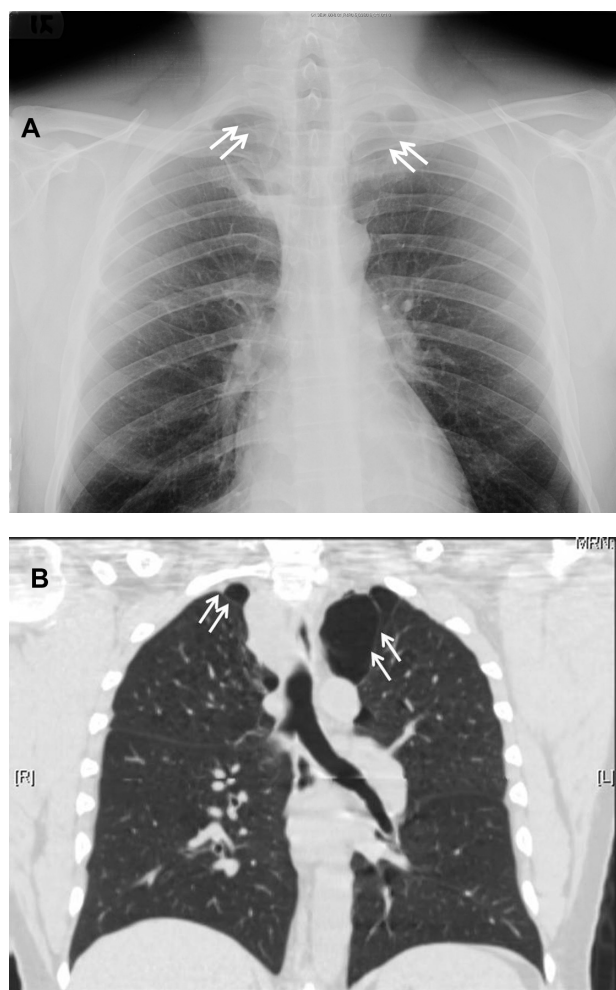


Figure 3. Chest radiograph at 4 month follow-up from admission, the inferior edge of bilateral apical lung bullae has now returned superiorly (double white arrows), indicating the auto collapse of bullae bilaterally (A). Computer tomography confirms the chest radiograph finding (B), lower borders of the bullae have arisen (double white arrows).

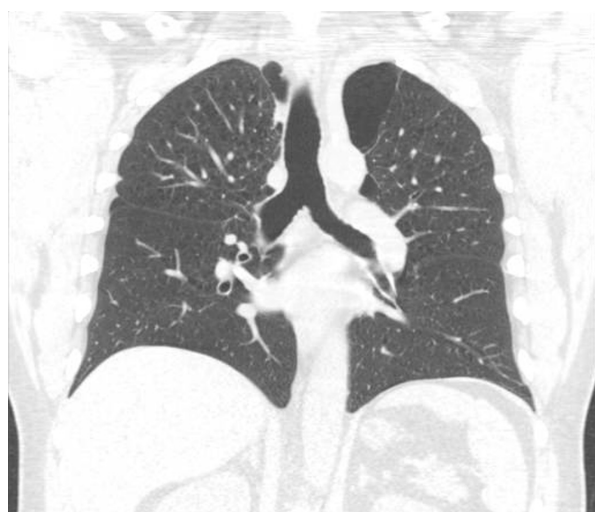

Figure 4. Computer tomography performed one year later shows no change in the growth of the apical bullae.

Peters et al discusses a series of patients that underwent serial follow-up with chest x-rays and bronchoscopy, while being managed with antibiotic therapy.¹⁰ All of these patients had a complete resolution of symptoms and air fluid levels in a time period of 2 to 32 weeks.

This patient was not initially ordained for surgery due to his pneumonia, and at the very least, we anticipated bullectomy would be indicated after its resolution. Much to our surprise, conservative management yielded results that precluded him from having any indication for surgical intervention. A surveillance chest x-ray performed at 4 months' time from admission demonstrated absolute clearance of his bilateral upper lobe bullae (Fig. 3A). Long-term follow-up with a CT-scan was completed, as it is unclear whether the bullae would recur with time and continued air trapping. A follow up CT-scan performed on June 2012 revealed no regression of the lung markings and no expansion of the bullae in the upper lobes (Fig. 4).

This case presents a paralleled progression of clinical symptoms with chest x-ray findings. The conservative management with antibiotic treatment resolved the symptoms of shortness of breath and fever. The Cardiothoracic Surgery department was consulted, as bullectomy is indicated for patients who have complications related to bullous disease such as infection or pneumothorax.¹¹ Surprisingly, as the patient was followed by the multi-disciplinary team, there was an eventual spontaneous regression of all lung pathology and clinical symptoms.

We all understand that even those patients who undergo bullectomy may not have outright improvement in clinical symptoms. With this knowledge, this case study demonstrates prudence in implementing conservative therapy. Rubin and Buchberg showed that fluid resorption may be associated with significant resolution of the bulla (autobullectomy).¹² This case portrays a similar scenario. It is not clear if the antibiotic therapy had a factor in the overall improvement of his condition, but based on other similar reports, this possibility cannot be ruled out.^{9,13,14} The regression of the bullae is shown in a clear manner through CT and X-ray images. The 1-year follow-up to monitor continued air trapping, which was completed because the resorption could reverse with time, supports the therapeutic management taken. This case supports the implementation of conservative management in patients with significant chronic bullous disease.



Author Contributions

Case Report presentation and discussion: FR, MS, VS. Analyzed the data: DP, ED, NG. Wrote the first draft of the case report: DP, MS. Contributed to the writing of the case report: DP, ED, MS. Agree with case report's results and conclusion: FR, JN, MS. Made critical revisions and approved final version: FR, JN, VS. All authors reviewed and approved of the final case report.

Funding

Author(s) disclose no funding sources.

Competing Interests

Author(s) disclose no potential conflicts of interest.

Disclosures and Ethics

As a requirement of publication the authors have provided signed confirmation of their compliance with ethical and legal obligations including but not limited to compliance with ICMJE authorship and competing interests guidelines, that the article is neither under consideration for publication nor published elsewhere, of their compliance with legal and ethical guidelines concerning human and animal research participants (if applicable), and that permission has been obtained for reproduction of any copyrighted material. This article was subject to blind, independent, expert peer review. The reviewers reported no competing interests.

References

1. Thurlbeck WM. Pathophysiology of chronic obstructive pulmonary disease. *Clin Chest Med*. 1990;11(3):389–403.
2. Palla A, Desideri M, Rossi G, et al. Elective surgery for giant bullous emphysema: a 5-year clinical and functional follow-up. *Chest*. 2005;128(4):2043–50.
3. Chandra D, Rose SR, Carter RB, Musher DM, Hamill RJ. Fluid-containing emphysematous bullae: a spectrum of illness. *Eur Respir J*. 2008;32(2):303–6.
4. Bhattacharyya P, Sarkar D, Nag S, Ghosh S, Roychoudhury S. Transbronchial decompression of emphysematous bullae: a new therapeutic approach. *Eur Respir J*. 2007;29(5):1003–6.
5. Greenberg JA, Singhal S, Kaiser LR. Giant bullous lung disease: evaluation, selection, techniques, and outcomes. *Chest Surg Clin N Am*. 2003;13(4):631–49.
6. Schipper PH, Meyers BF, Battafarano RJ, Guthrie TJ, Patterson GA, Cooper JD. Outcomes after resection of giant emphysematous bullae. *Ann Thorac Surg*. 2004;78(3):976–82.
7. Palla A, Desideri M, Rossi G, et al. Elective surgery for giant bullous emphysema: a 5-year clinical and functional follow-up. *Chest*. 2005;128(4):2043–50.
8. Gaensler EA, Jederlinic PJ, Fitz Gerald MX. Patient work-up for bullectomy. *J Thorac Imaging*. 1986;1(2):75–93.
9. Douglas AC, Grant IW. Spontaneous closure of large pulmonary bullae: a report on three cases. *Br J Tuberc Dis Chest*. 1957;51(4):335–8.
10. Peters JI, Kubitschek KR, Gotlieb MS, Awe RJ. Lung bullae with air-fluid levels. *Am J Med*. 1987;82(4):759–63.
11. Vigneswaran WT, Townsend ER, Fountain SW. Surgery for bullous disease of the lung. *Eur J Cardiothorac Surg*. 1992;6:427–30.
12. Rubin EH, Buchberg AS. Capricious behavior of pulmonary bullae developing fluid. *Dis Chest*. 1968;54(6):546–9.
13. Stark P, Gadziala N, Greene R. Fluid accumulation in preexisting pulmonary air spaces. *AJR Am J Roentgenol*. 1980;134(4):701–6.
14. Henao-Martinez AF, Fernandez JF, Adams SG, Restrepo C. Lung bullae with air-fluid levels: what is the appropriate therapeutic approach? *Respir Care*. 2012;57(4):642–5.