

CASE REPORT

OPEN ACCESS

Full open access to this and thousands of other papers at <http://www.la-press.com>.

Pregnancy Complicated by Cervical Varix and Low-Lying Placenta: A Case Report

Yasushi Kurihara, Daisuke Tachibana, Masatomo Teramae, Makiko Matsumoto, Hiroyuki Terada, Toshiyuki Sumi, Masayasu Koyama and Osamu Ishiko

Department of Obstetrics and Gynecology, Osaka City University Graduate School of Medicine, Asahimachi, Osaka, Japan. Corresponding author email: m2067127@med.osaka-cu.ac.jp

Abstract: We present a case of cervical varix and low-lying placenta. A cesarean section was performed because of the risk of bleeding with vaginal delivery; hemostasis was achieved using z sutures at the bleeding points. After delivery, the cervical varix decreased dramatically in size. It is important to recognize the clinical features and available treatments for cervical varix.

Keywords: cervical varix, low-lying placenta, hemorrhage

Japanese Clinical Medicine 2013:4 21–24

doi: [10.4137/JCM.S11276](https://doi.org/10.4137/JCM.S11276)

This article is available from <http://www.la-press.com>.

© the author(s), publisher and licensee Libertas Academica Ltd.

This is an open access article published under the Creative Commons CC-BY-NC 3.0 license.

Introduction

Although vulvar varices complicate approximately 15% of all pregnancies and rarely cause bleeding during pregnancy and delivery, a cervical varix, which is rare, can cause massive obstetric hemorrhage. Its diagnosis, preferable mode of delivery, and prognosis have not been established. We present a case of a cervical varix with a low lying placenta.

Case Report

A 40-year-old Japanese woman (gravida 2, para 1) presented at our hospital at 18 weeks' gestation for prenatal care. At 22 weeks' gestation, transvaginal ultrasonography revealed a low lying placenta; the placenta was located on the lower side of the posterior uterine wall, with its lower edge near the internal cervical os. An ultrasound performed at 34 weeks revealed that the cervical tissue had been replaced with a dilated venous plexus with abundant blood flow (Fig. 1). We diagnosed this condition as a large cervical varix. However, we found no specific abnormal findings with the speculum examination. Vaginal bleeding did not occur during her pregnancy. A vaginal delivery was extremely likely to cause catastrophic bleeding; therefore, we performed a planned cesarean section at 37 weeks, yielding a healthy female infant (3,345 g; Apgar score 8/10 (1/5 min)). The placenta was easily separated manually. After placental separation, inspection of the cervical lumen and the lower segment lumen revealed dilated blood vessels protruding into the lumen. Some vessels ruptured with resultant active bleeding, which required several hemostatic Z-sutures (Fig. 2). The estimated blood loss was 3,610 mL; 4 units of packed red blood cells were transfused. The size of the cervical varix decreased dramatically postpartum (Fig. 3). A varix was not present in the cervix two months postpartum.

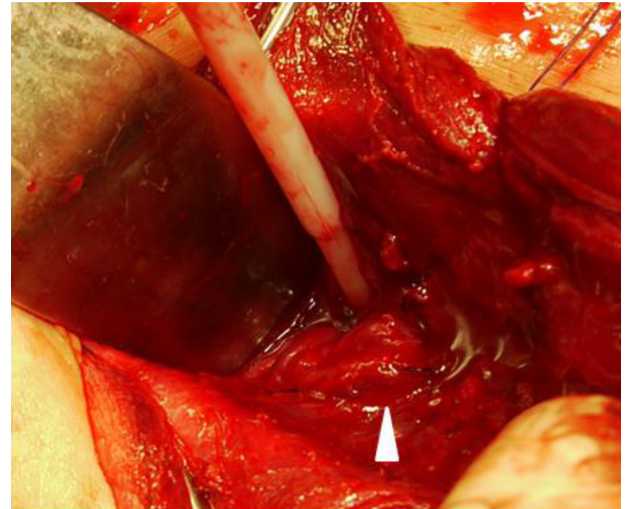


Figure 2. Photo during operation.

Note: Arrow head shows cervical varix with active bleeding.

Comments

We describe a pregnant woman with cervical varices in whom a cesarean section was performed. Even with the cesarean section, active bleeding ensued, which required a blood transfusion and hemostatic sutures.

Although the etiology of cervical varices during pregnancy is unclear, a lower placental location, a placenta previa, and a low-lying placenta are considered to be culprits. A lower placental location increases the blood flow to the cervix, leading to the development of cervical venous dilatation, and eventually cervical varices. Hormonal dynamic changes, increased abdominal pressure, and the enlarged uterus that is a result of pregnancy will compress the inferior vena cava and pelvic veins, thus also accelerating varix formation. Although this is rare occurrence, maternal exposure to diethylstilbestrol (DES) in utero causes vascular malformations of pelvic organs in their daughters, which has also been considered to be causative for this disorder.^{1,2}

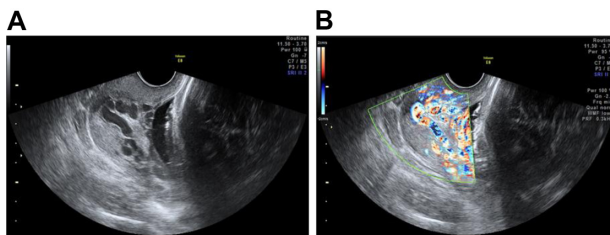


Figure 1. Transvaginal ultrasound image at 34 weeks of gestation shows severely dilated tortuous blood vessels replacing most of the normal cervical tissue (B) power Doppler.

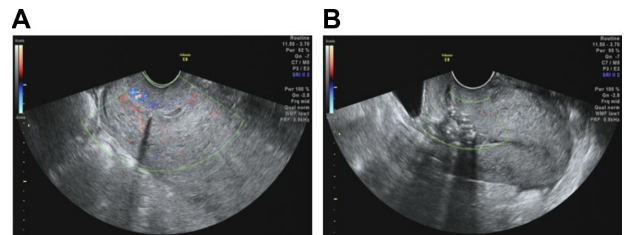


Figure 3. Transvaginal ultrasound image of the uterus 2 days postpartum (A) and 2 months postpartum (B).

Table 1. Summary of published cases of cervical varices in pregnancy.

Reference	Maternal age (years)	G/P	GA at diagnosis	Bleeding during pregnancy	Treatment	Placental location	Mode of delivery	GA at delivery	Blood loss (mL)	Birth weight (g)	Apgar score 1 min/5 min
Follem et al ²	31	3/3	22	Yes	Packing, bed rest	NS	CS	35.5	NS	NS	NS
	32	4/1	13	No	Cerclage, bed rest	NS	CS	31	NS	1700	NS
Fleming and Anderson ¹	32	2/0	28	Yes	Bed rest	NS	TVD	Term	NS	NS	NS
	26	2/1	25	No	Cerclage	NS	CS	36.5	NS	3239	NS
Hurton et al ⁸	33	2/0	33	Yes	Tocolytics, hysterectomy	Not low	CS	34	5,000	NS	7/8
Yoshimura et al ⁷	34	1/0	18	Yes	Tocolytics, bed rest	Previa	CS	27	920	1,090/920	5/7
Kusanovic et al ⁶	26	3/0	21	Yes	Tocolytics, packing, blood transfusion	Low lying	CS	32	NS	2,160	8/9
Kumazawa et al ⁵	30	1/0	27	Yes	Tocolytics, packing	Previa	CS	32	1,814	1,655	6/8
Sammour et al ⁴	36	1/0	23	No	Bed rest	Low lying	CS	37	1,000	3,695	8/10
Sukur et al ³	40	2/1	37	Yes	No	Previa	CS	37	1,500	2,930	NS
Present case	40	2/1	34	No	No	Low lying	CS	37	3,610	3,345	8/10

Abbreviations: CS, cesarean section; GA, gestational age; NS, not specified; TVD, transvaginal delivery.



While vulvar varices during pregnancy are frequently observed and they rarely cause clinically significant bleeding,⁹ cervical varices can cause massive obstetric hemorrhage. A PubMed search yielded only 10 case reports describing cervical varices.^{1–8} In seven of 11 cases (including our case), prenatal bleeding occurred and required termination of pregnancy; in five cases abnormal placental location was recognized (Table 1). Interestingly, two of 10 previously reported cases were from Japan,^{5,7} and the present case was also a Japanese woman. In our case, grey-scale with color Doppler ultrasound detected this abnormality. In the last decade, transvaginal color Doppler ultrasound has been employed in Japan and it is becoming a general-purpose imaging modality in obstetrics. This may be the reason why three out of 11 cases have been reported from Japan. In addition, without the employment of color Doppler, the disorder may remain unrecognized and the cervical variceal rupture could be an undiagnosed factor in cases of massive perinatal hemorrhage. Thus, the incidence of cervical varicosities might be higher than the expected level calculated from earlier case reports.

Due to DES exposure, the placement of a cervical cerclage was performed in two cases.^{1,2} Although bleeding did not occur during these pregnancies, hemorrhagic risk from a cerclage suture does exist. Thus, this surgical option remains controversial.

The cervical varices in the present case ruptured with significant hemorrhage, despite the cesarean delivery. We extended the uterine incision to the cervix and repaired the varices under direct vision. As a consequence, we achieved hemostasis. A hysterectomy or transarterial embolization was avoided. We assume that the cervical varix can be identified by a trans-vaginal ultrasound, with the awareness of its possible coexistence with abnormal placentation; thus, a management strategy can be developed to prevent postpartum hemorrhage.

Author Contributions

Conceived and designed the experiments: MM, HT, DT. Analyzed the data: YK, MT, MM. Wrote the first draft of the manuscript: YK, DT. Contributed to the writing of the manuscript: YK, MT, MM, DT. Agree with manuscript results and conclusions: YK,

MT, MM, DT. Jointly developed the structure and arguments for the paper: MM, HT, DT. Made critical revisions and approved final version: TS, MK, OI. All authors reviewed and approved of the final manuscript.

Funding

Author(s) disclose no funding sources.

Competing Interests

Author(s) disclose no potential conflicts of interest.

Disclosures and Ethics

As a requirement of publication author(s) have provided to the publisher signed confirmation of compliance with legal and ethical obligations including but not limited to the following: authorship and contributorship, conflicts of interest, privacy and confidentiality and (where applicable) protection of human and animal research subjects. The authors have read and confirmed their agreement with the ICMJE authorship and conflict of interest criteria. The authors have also confirmed that this article is unique and not under consideration or published in any other publication, and that they have permission from rights holders to reproduce any copyrighted material. Any disclosures are made in this section. The external blind peer reviewers report no conflicts of interest.

References

1. Fleming AD, Anderson TL. Cervical AV malformation with in utero DES exposure. *Nebr Med J*. 1993;78:138–9.
2. Follen MM, Fox HE, Levine RU. Cervical vascular malformation as a cause of antepartum and intrapartum bleeding in three diethylstilbestrol-exposed progeny. *Am J Obstet Gynecol*. 1985;153:890–1.
3. Sukur YE, Yalcin I, Kahraman K, Soylemez F. Cervical varix complicating marginal placenta previa: a unique coexistence. *J Obstet Gynaecol Res*. 2011;37:1515–7.
4. Sammour RN, Gonen R, Ohel G, Leibovitz Z. Cervical varices complicated by thrombosis in pregnancy. *Ultrasound Obstet Gynecol*. 2011;37:614–6.
5. Kumazawa Y, Shimizu D, Hosoya N, Hirano H, Ishiyama K, Tanaka T. Cervical varix with placenta previa totalis. *J Obstet Gynaecol Res*. 2007;33:536–8.
6. Kusanovic JP, Soto E, Espinoza J, et al. Cervical varix as a cause of vaginal bleeding during pregnancy: prenatal diagnosis by color Doppler ultrasonography. *J Ultrasound Med*. 2006;25:545–9.
7. Yoshimura K, Hirsch E, Kitano R, Kashimura M. Cervical varix accompanied by placenta previa in twin pregnancy. *J Obstet Gynaecol Res*. 2004;30:323–5.
8. Hurton T, Morrill H, Mascola M, York C, Bromley B. Cervical varices: an unusual etiology for third-trimester bleeding. *J Clin Ultrasound*. 1998;26:317–9.
9. Stansby G. Women, pregnancy, and varicose veins. *Lancet*. 2000;355:1117–8.