

CASE REPORT

OPEN ACCESS

Full open access to this and thousands of other papers at <http://www.la-press.com>.

Torsion of a Uterine Leiomyoma: A Case Report and Review of the Literature

N.M. Ward, M.K. Frey and B.D. Shaktman

Department of Obstetrics and Gynecology, New York Presbyterian Hospital, Weill Cornell Medical College, New York, NY, USA. Corresponding author email: mkf2002@nyp.org

Abstract: A 55 year-old woman presented with abdominal pain. Transvaginal ultrasonography demonstrated an enlarged fibroid uterus. She underwent total abdominal hysterectomy and bilateral salpingo-oophorectomy and was found to have torsion of a large pedunculated leiomyoma. There are fewer than 10 cases reported in the literature of torsion of a uterine leiomyoma.

Keywords: leiomyoma, fibroid, torsion, pedunculated

Clinical Medicine Insights: Women's Health 2011;4 51–54

doi: [10.4137/CMWH.S6780](https://doi.org/10.4137/CMWH.S6780)

This article is available from <http://www.la-press.com>.

© the author(s), publisher and licensee Libertas Academica Ltd.

This is an open access article. Unrestricted non-commercial use is permitted provided the original work is properly cited.



Introduction

Uterine leiomyomata are benign tumors that arise from the smooth muscle cells of the myometrium. Uterine leiomyomata are the most common gynecologic tumors, clinically apparent in approximately 25 percent of reproductive aged women and noted on pathologic exam in approximately 80 percent of surgically excised uteri.¹ Although usually asymptomatic, acute torsion of a pedunculated leiomyoma causing severe abdominal pain is a rare complication and can be a surgical emergency when associated with infarction, necrosis, ischemic gangrene or peritonitis.^{2,3} To date, there are fewer than 10 cases reported in the literature of torsion of a uterine leiomyoma in non-pregnant women.

Case

A 55 year-old nulliparous woman presented to the emergency room at an outside institution with severe, sudden onset lower abdominal pain associated with subjective fever and nausea. Seven years prior, the patient's primary gynecologist noted an enlarged uterus on physical exam and follow-up sonography demonstrated a 15 cm uterine leiomyoma. Unfortunately, as this initial hospital admission occurred at an outside hospital, we do not have the medical records. However, per the patient's report she underwent a transvaginal sonogram that revealed an enlarged uterus measuring approximately 20 cm. The patient's laboratory values were within normal limits, she was afebrile and appendicitis and other etiologies of acute abdominal pain were excluded. She was admitted for pain management with oral narcotics for presumed leiomyoma-related abdominal pain. Her symptoms resolved and no further evaluation or intervention was pursued. She was discharged on hospital day number 3 with a plan for non-urgent surgical management of uterine leiomyomata.

One week later the patient presented for outpatient follow-up with a gynecologist. She underwent a transvaginal sonogram that demonstrated an enlarged uterus measuring approximately 25.0 × 12.8 × 18.2 cm that extended up to the xiphoid process and contained multiple small leiomyomata (Fig. 1). On physical exam she had an enlarged uterus, measuring approximately 20 cm, however, no abdominal tenderness or other exam abnormalities were noted. She was afebrile and had no leukocytosis (white blood cell count 9.3). The patient

was scheduled for a total abdominal hysterectomy and bilateral salpingo-oophorectomy (TAH/BSO).

The patient was admitted to our hospital two weeks following the acute episode of abdominal pain for scheduled surgery. During the interim period and upon this hospital admission she reported feeling well, denying further abdominal pain or fever. A laparotomy was performed through a Pfannensteil incision revealing a large necrotic-appearing pedunculated leiomyoma, emerging from the fundus of the uterus and measuring 17.0 × 15.0 × 12.0 cm. When attempting to mobilize the leiomyoma, it was found to be twisted approximately four times around its vascular pedicle, with a small component, measuring approximately 2.0 × 2.0 cm, that was adherent to the sigmoid colon. Adhesions between the large intestine and the leiomyoma were taken down and the leiomyoma was removed using electrocautery at the pedicle. The patient was found to have multiple additional small pedunculated leiomyomata. She underwent an uncomplicated TAH/BSO. According to the pathology report, the leiomyoma weighed 1950 grams with a circumscribed white whorled appearance. There was one region of discoloration with hemorrhage and necrosis. The post-operative course was uncomplicated and the patient was discharged home on post-operative day number 4.

Comment

Uterine leiomyomata are the most common gynecologic tumors, clinically apparent in approximately 25 percent of reproductive aged women and noted on pathologic exam in approximately 80 percent of surgically excised uteri.¹ Although usually asymptomatic, a pedunculated leiomyoma can become ischemic due to torsion of the vascular pedicle which can cause acute onset severe abdominal pain. Although torsion of uterine leiomyoma is included in most gynecologic texts, a PubMed literature search on this topic yields scant case reports (Table 1). Tordera et al⁴ provide the first case report of an acute abdomen caused by torsion of a calcified pedunculated myoma in 1952. Since that time, there have been fewer than 10 reported cases of torsion of a uterine leiomyoma in non-pregnant women.

According to the available case reports, torsion of a uterine leiomyoma usually presents as sudden onset severe abdominal pain caused by ischemia of

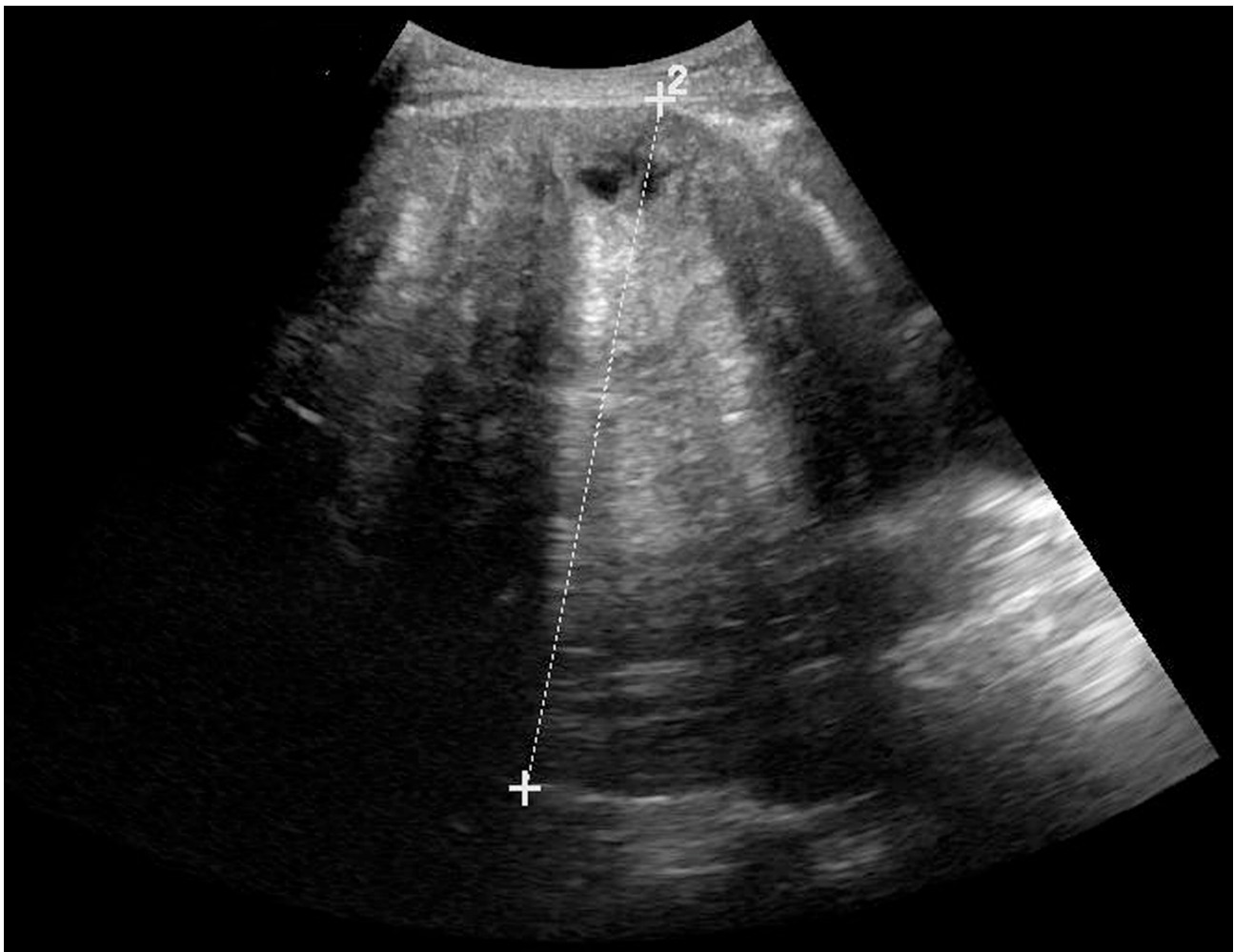


Figure 1. Transvaginal sonogram demonstrating enlarged uterus measuring approximately 25.0 × 12.8 × 18.2 cm that extends up to the xiphoid process and contains multiple small leiomyomata.

Table 1. Review of literature on torsion of uterine leiomyoma in nonpregnant patients.

Publication	Patient age	Clinical presentation	Method of diagnosis	Treatment
Tsai et al ³	38	Abdominal pain	Abdominal Ultrasound	Abdominal Myomectomy
Gaym and Tilahun ⁸	20	Abdominal pain, amenorrhea	Transvaginal Ultrasound	Abdominal Myomectomy
Marcotte-Bloch et al ⁶	32	Pelvic pain, bowel disorder, intermittent constipation and diarrhea, vomiting, polyuria	Abdominal and Transvaginal Ultrasound, Abdominal CT scan, Pelvic MRI	Laparoscopic Myomectomy
Roy et al ⁷	30	Pelvic pain, nausea, urinary frequency	Abdominal Ultrasound, Abdominal CT scan	Abdominal Myomectomy
Mickel et al ⁹	35	Postpartum day 16 after vaginal delivery, abdominal pain, ileus		Abdominal Myomectomy
Articles with no abstract or text available in English				
Publication	Article title			
Yuksel-Hatz et al ¹⁰	Torsion of a pedunculated subserous myoma—a rare differential diagnosis of the acute abdomen			
Tordera et al ⁴	Acute abdomen caused by calcified pedunculated myoma			
Gabor et al ¹¹	Giant uterine cyst and peduncular torsion of myoma			



the vascular pedicle. The differential diagnosis for this pain includes ovarian or adnexal torsion, ovarian tumor, necrotic infarction of a leiomyoma and, less commonly, leiomyoma torsion. Transvaginal ultrasound can identify a lesion lateral to the uterus however a definitive diagnosis cannot be made and the pedicle is often too thin for identification with this imaging technique. MRI is considered the best imaging modality for uterine leiomyoma when ultrasound is inconclusive.⁵ To date, there are no studies comparing the sensitivity and specificity of MRI to CT for evaluation of torsion of a leiomyoma. MRI may be a better diagnostic technique, however, access to MRI is not widely available, and therefore CT is frequently used. Marcotte-Bloch et al⁶ report a case of torsion of a uterine leiomyoma where the pedicle was noted and diagnosis made based on MRI. Roy et al⁷ report a case where diagnosis was made based on CT scan demonstration of normal ovaries and contrast enhancement of the uterine portion connected to the mass.

Regarding this case, the patient presented to the emergency room with severe acute abdominal pain and was discharged with resolution of symptoms, however, without a clear etiology for the pain. The diagnosis was not revealed until the time of laparotomy for the treatment of what were presumed to be chronic stable leiomyomata. The diagnosis of torsion of a pedunculated uterine leiomyoma was not apparent on transvaginal sonogram, but perhaps a CT scan or MRI at the first hospital visit would have allowed for a more timely diagnosis of her underlying gynecologic pathology. Although she remained asymptomatic after the initial hospitalization, she was at risk for ischemic gangrene, peritonitis and disruption or torsion of the adherent large bowel.

Source

Case report from patient at New York Presbyterian Hospital-Weill Cornell Medical College.

Disclosure

This manuscript has been read and approved by all authors. This paper is unique and is not under consideration by any other publication and has not been published elsewhere. The authors and peer reviewers of this paper report no conflicts of interest. The authors confirm that they have permission to reproduce any copyrighted material.

References

1. Cramer S, Patel A. The frequency of uterine leiomyomas. *Am J Clin Pathol*. 1990;94:435–8.
2. Gupta S, Manyonda I. Acute complications of fibroids. *Best Pract Res Clin Obstet Gynaecol*. 2009;23:609–17.
3. Tsai Y, Yeats S, Jeng C, Chen S. Torsion of a uterine leiomyoma. *Taiwan J Obstet Gynecol*. 2006;45:333–5.
4. Tordera A, Bello T, Bouteiller J. Acute abdomen caused by calcified pediculated myoma. *Dia Med*. 1952;24:1523–4.
5. Vandermeer FQ, Wong-You-Cheong JJ. Imaging of acute pelvic pain. *Clin Obstet Gynecol*. 2009;52:2–20.
6. Marcotte-Bloch C, Novellas S, Buratti M, Caramella T, Chevallier P, Bruneton J. Torsion of a uterine leiomyoma: MRI features. *Clin Imaging*. 2007;31:360–2.
7. Roy C, Bierry G, El Ghali S, Buy X, Rossini A. Acute torsion of uterine leiomyoma: CT features. *Abdom Imaging*. 2005;30:120–3.
8. Gayma A, Tilahun S. Torsion of pedunculated subserous myoma—a rare cause of acute abdomen. *Ethiop Med J*. 2007;45:203–7.
9. Mickel I, Bollmann R, Lau HU. Torsion of the myoma pedicle as a rare cause of ileus in puerperium. *Geburtshilfe Frauenheilkd*. 1995;55:721–3.
10. Yüskel-Hatz S, Chilla B, Tokic I, Singer G, Hohl M, Kubik-Huch R. Torsion of a pedunculated subserous myoma—a rare differential diagnosis of the acute abdomen. *Praxis (Bern 1994)*. 2010;99:45–50.
11. Gabor P, Traub A. Giant uterine cyst and peduncular torsion of myoma. *Orv Hetil*. 1958;99:1262–3.

Publish with **Libertas Academica** and every scientist working in your field can read your article

“I would like to say that this is the most author-friendly editing process I have experienced in over 150 publications. Thank you most sincerely.”

“The communication between your staff and me has been terrific. Whenever progress is made with the manuscript, I receive notice. Quite honestly, I’ve never had such complete communication with a journal.”

“LA is different, and hopefully represents a kind of scientific publication machinery that removes the hurdles from free flow of scientific thought.”

Your paper will be:

- Available to your entire community free of charge
- Fairly and quickly peer reviewed
- Yours! You retain copyright

<http://www.la-press.com>