

## CASE REPORT

### OPEN ACCESS

Full open access to this and thousands of other papers at <http://www.la-press.com>.

# Isoniazid-Induced Severe Hepatotoxicity: An Infrequent but Preventable Cause of Liver Failure in Children Treated for Latent Tuberculosis Infection

Dan Desrochers<sup>1</sup>, Regino P. González-Peralta<sup>2</sup>, Daniel T. McClenathan<sup>1</sup>, Michael J. Wilsey Jr<sup>1</sup> and Allah Haafiz<sup>2</sup>

<sup>1</sup>Department of Pediatrics, University of South Florida College of Medicine, Tampa, Florida, USA.

<sup>2</sup>Pediatric Hepatology and Liver Transplantation, Division of Pediatric Gastroenterology, Hepatology and Nutrition, University of Florida College of Medicine and Shands Children's Hospital, Gainesville, Florida, USA.

Corresponding author email: [haafiab@peds.ufl.edu](mailto:haafiab@peds.ufl.edu)

**Abstract:** Isoniazid (INH) monotherapy has gained widespread acceptance as an efficacious therapy for latent tuberculosis infection (LTBI) especially in low-prevalence settings. Although INH related hepatotoxicity is well recognized, progression to severe liver dysfunction requiring care at a transplant center remains unpredictable. We report the management of a five year-old girl who developed progressive liver failure due to INH prophylaxis. This highlights the potential severity of INH related hepatic injury and underscores the significance of vigilant clinical monitoring throughout the duration of the therapy in children.

**Keywords:** isoniazid, hepatotoxicity, latent tuberculosis infection

*Clinical Medicine Insights: Pediatrics* 2011;5 9–13

doi: [10.4137/CMPed.S6406](https://doi.org/10.4137/CMPed.S6406)

This article is available from <http://www.la-press.com>.

© the author(s), publisher and licensee Libertas Academica Ltd.

This is an open access article. Unrestricted non-commercial use is permitted provided the original work is properly cited.



## Introduction

Tuberculosis is a major global public health problem affecting millions of new cases each year. A significant proportion the new cases, especially in low-prevalence settings such as seen in affluent countries result from the reactivation of latent tuberculosis infection (LTBI). Individuals with LTBI are typically asymptomatic, have normal chest radiograph, but have a positive purified protein derivative (PPD) skin test. A variety of treatment regimens have been evaluated for the management of LTBI, with the aim of reducing the likelihood of subsequent reactivation of tuberculosis. Isoniazid (INH) is currently considered the most appropriate therapy in children with LTBI.<sup>1</sup> Although INH related hepatotoxicity is well recognized, the burden of severe liver dysfunction requiring liver transplantation due to this therapy in children remains obscure given the lack of studies in this population. Moreover, development of liver failure can occur even with the discontinuation of INH at the onset of symptoms of liver dysfunction.<sup>2</sup> Therefore, documentation of such cases is a vital step to enhancing our comprehension of how to manage a given patient with liver failure due to INH therapy. Similarly, careful analysis of these cases may have a significant impact on the evolution of certain aspects of guidelines for LTBI management in children.

Herein, we report a five year-old girl who developed progressive hepatic failure associated with INH prophylaxis for LTBI. Liver histology was consistent with drug-induced injury and the patient favorably responded to supportive care and corticosteroid therapy. This case highlights the potential severity of INH related hepatic injury and underscores the significance of vigilant clinical monitoring throughout the duration of the therapy in children.

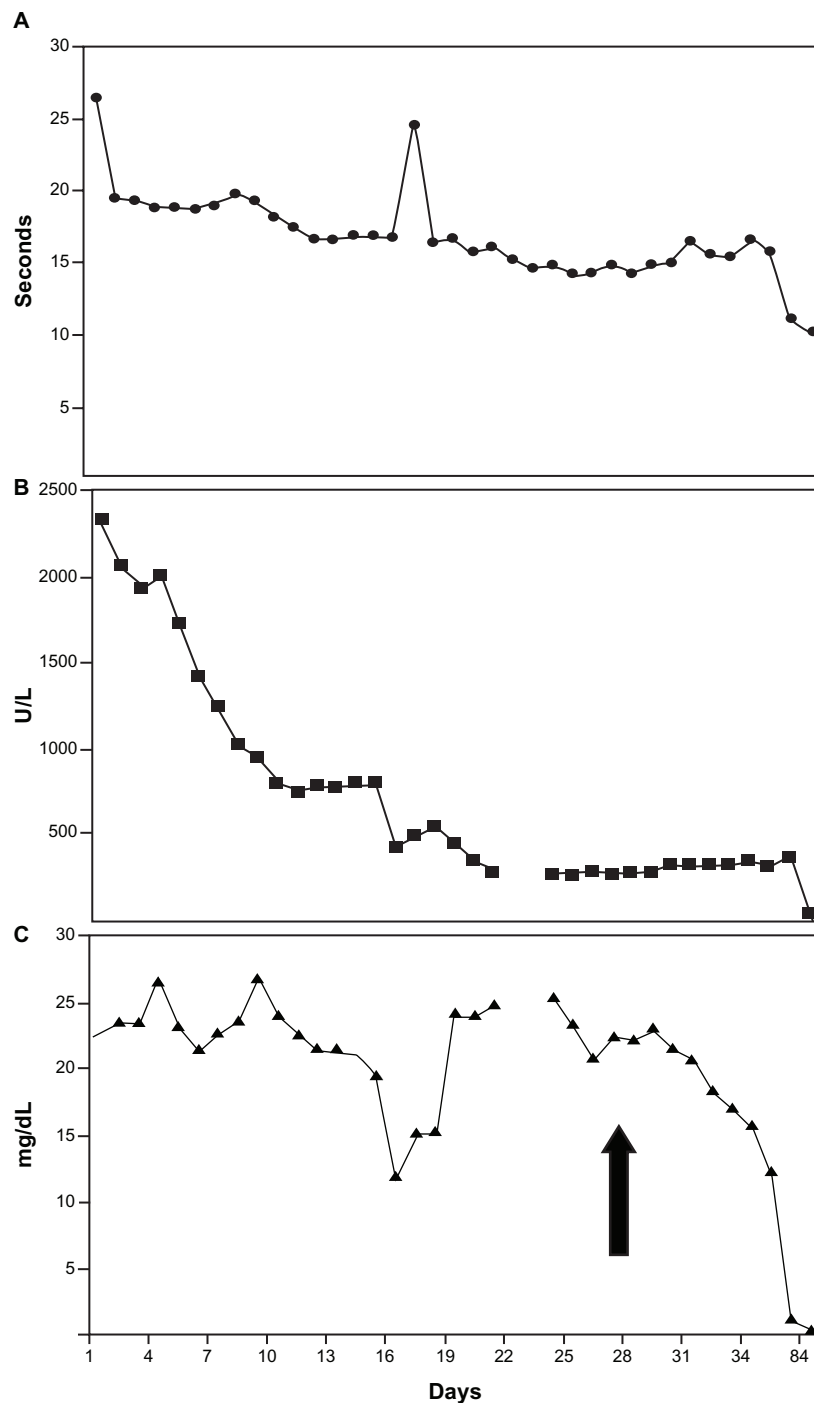
## Case Report

A previously healthy five year-old Hispanic female presented with a three week history of progressive anorexia and jaundice. At the time of presentation, she had only three days left to complete a nine-month course of isoniazid (INH) monotherapy for a positive PPD skin test and a normal chest radiograph performed at the local health department. She was born in the United States but spent several months with her

family in Mexico one year before PPD testing. The patient received oral INH and vitamin B6 (25 mg) twice weekly by directly observed therapy. She reported to clinic each month for follow-up, and her initial oral 350 mg INH dose was increased to 400 mg twice weekly six months after initiation of therapy to adjust for weight. Apart from Echinacea and multivitamins, no over the counter medications were given during the prescribed INH therapy. A few days prior to hospitalization, comprehensive metabolic panel at a local clinic revealed an aspartate aminotransferase (AST) of 2929 U/L, alanine transaminase (ALT) of 1941 U/L (normal < 45 for both), and total bilirubin of 20.5 mg/dL (normal < 0.8 mg/dL). At the time of hospitalization, the patient had marked conjunctival icterus and dermal jaundice but she was afebrile and had no acute distress. Physical findings were otherwise normal except for a mildly distended, non-tender abdomen and hepatomegaly with a liver edge palpable four centimeters below the right costal margin at the mid-clavicular line on inspiration. The spleen was not enlarged and there were no cutaneous stigmata of chronic liver disease. Neurologically, the patient had normal mental status, strength, tone, and deep tendon reflexes. Initial laboratory analysis showed albumin 3.6 mg/dL (4.0–5.3 g/dL), alkaline phosphatase 399 U/L (130–560 U/L), AST 3485 U/L (normal 5–45 U/L), ALT 2327 (normal 5–45)U/L, GGT 48 U/L (normal 5–24 U/L), ammonia 45  $\mu$ mol/L (normal 17–68  $\mu$ mol/L), PT 26.1 seconds (normal 10.1–12 seconds), and PTT 47.7 seconds (normal 26–36 seconds). Hepatitis A, B and C virus, cytomegalovirus and human immunodeficiency virus serology, alpha-1 antitrypsin and ceruloplasmin concentrations, antinuclear, smooth-muscle and liver-kidney-microsomal antibodies and chest radiograph yielded negative-normal results. Results of Epstein-Barr virus serology were consistent with past infection. She developed progressive pruritis despite ursodeoxycholic acid therapy [total bilirubin 24.6 mg/dL, direct bilirubin 15.6 mg/dL (0 to 0.4 mg/dL)] and remained mildly coagulopathic (PT 16.1 seconds) despite daily intravenous vitamin K. Attempted transjugular liver biopsy was unsuccessful and she was transferred for formal liver transplant evaluation. Histological examination of liver tissue obtained by laparoscopy showed lymphoplasmacytic infiltration in portal, interface and

lobular areas, with hepatic architectural collapse, fibrosis and severe cholestasis. These histological abnormalities were consistent with drug induced injury and systemic corticosteroids were therefore started. Within a few days, her overall condition including coagulopathy and liver tests improved and she was

discharged home. The corticosteroids were gradually weaned over the next four months. Liver size and biochemical profile normalized over this time. Six months after discontinuing corticosteroids, the patient was clinically well and without residual liver dysfunction (Fig. 1).



**Figure 1.** Course of selected laboratory tests depicted over time. Pannel **A)** Prothrombin time; **B)** alanine aminotransferase; and **C)** total bilirubin. Arrow indicates initiation of corticosteroid therapy.



## Discussion

Centers for Disease Control and Prevention (CDC) recommends that children with LTBI should be treated with INH prophylaxis for 9 months as a daily self-administered therapy at a dose of 10–20 mg/kg (maximum dose 300 mg) or twice weekly directly observed therapy at a dose of 20–40 mg/kg (maximum dose 900 mg). These recommendations are accessible through CDC web page,<sup>3</sup> which aim to not only cure the individual patient, but also minimize the transmission of *Mycobacterium tuberculosis* to healthy populations. Indeed due to the public health perspective, CDC takes a vigorous stand for the successful completion of INH therapy. Whereas this therapy is generally well tolerated with excellent results, the development of significant liver dysfunction is well known in pediatric patients.<sup>2,4–8</sup> We report this case to: a) underscore the significance of optimal clinical monitoring, and a timely cessation of therapy in the event of significant hepatotoxicity; and b) to review the literature on severe liver dysfunction due to INH prophylaxis to ascertain if a common theme can be formulated for the identification and management of such cases.

Consistent with previously reported pediatric cases of INH-induced hepatotoxicity, the reasons for the severity of liver damage in our patient are unclear. History, clinical examination and laboratory evaluation provided no evidence of prior chronic liver disease and excluded other potential causes for liver disease. Whether or not Echinacea contributed to the hepatic insult in our patient is not known. Being a non-regulated dietary supplement, there is inadequate published data about the significance of Echinacea in liver injury. Similarly, younger age of our patient is also an unlikely contributor, because, INH-related liver dysfunction has been most often sited in adult population, although this may be at least partly due to a reporting bias. Similarly, continued use of INH for three weeks after the onset of progressive anorexia and jaundice prior to her presentation at the local health department may have significantly contributed to the liver injury. Although liver injury was noted to follow a chronic disease model (evident from liver biopsy), one can postulate that discontinuation of therapy three weeks earlier in her treatment might have averted progression to hepatic failure. Indeed similar reports of INH administration beyond the onset of hepatitis symptoms have been documented in children as the most likely reason for severe liver injury.<sup>7,9</sup> This

underscores the importance of appropriate training of the workers for direct observational therapy and educating the family about what to look for and what to do if symptoms of hepatotoxicity develop. In addition to allied health care workers and physicians prescribing INH for LTBI should, apart from clinical monitoring, ensure that parental education is reinforced at each monthly visit.<sup>10</sup> By the same token, in the case of non-English speaking families (such as the case presented here), the caregivers should be provided a summary of possible adverse effects, written in their native language along with specific instructions to follow in the event toxicity occurs. Because severe hepatotoxicity and death have been documented with continued INH therapy after the onset hepatitis,<sup>9</sup> the emphasis of the education should be on cessation of this drug at the very onset of symptoms of liver disease.

Similar to our case, at least thirteen children have been reported to undergo evaluation for orthotopic liver transplantation (OLT) due to INH-related hepatotoxicity indicating severe liver injury due to this therapy.<sup>2,4–8</sup> For example, Wu et al, through a survey of liver transplantation centers described 10 patients who required OLT due with INH-associated hepatic failure. In addition, this study reported that six children died as a result of INH hepatotoxicity without receiving a transplant.<sup>2</sup> Similar reports of significant morbidity and mortality due to INH associated liver injury have been made by others.<sup>11–13</sup> Apart from the monitoring issues discussed above, collectively, these reports raise the question of whether there any clinical or biochemical determinants of severe liver dysfunction, and if so, how to utilize these determinants to avoid significant morbidity and mortality for a given patient. Unfortunately, the pathogenesis of INH-related liver injury remains elusive, precluding the development of INH-hepatotoxicity-prediction models. Therefore, a priori forecasting about who will be at risk to develop severe INH-related liver injury remains insuperable at the moment. However, INH-related hepatotoxicity is believed to be mediated by mono-acetyl hydrazine, a metabolite of INH which is activated by Cytochrome P-450 (CYP) enzyme system, and detoxified by N-acetyltransferase-2.<sup>14</sup> The activity of both of these enzymes is well known to be influenced by genetic variability. For example, a constellation comprised of slow acetylator status coupled with CYP 2E1 genetic polymorphism is known to be a risk for INH related hepatotoxicity.<sup>15</sup> Similarly, concomitant



administration of rifampicin, a CYP-450 inducer, can significantly increase the risk of liver injury due to INH.<sup>16,17</sup> Although these insights are important for understanding the basis of liver injury, due to substantial costs, routine assessment of CYP 2E1 polymorphism or N-acetyltransferase-2 activity is not feasible. Therefore, to prevent acute or sub-acute liver failure due to INH, the emphasis remains on early detection of INH related hepatitis and avoiding concurrent administration of other hepatotoxic drugs such as rifampicin.

In summary, INH therapy for LTBI prophylaxis in children has been the standard of care for many years. Given the burden of active tuberculosis and a well accepted therapeutic appeal of INH for LTBI, any drastic amendments to decrease the duration of therapy are unlikely. Most children with subclinical hepatic damage recover completely while continuing INH therapy. However, due to poorly understood mechanisms, some patients may develop significant liver injury requiring care at a center with resources to perform liver transplantation. Early recognition and cessation of INH therapy is necessary to prevent the progression of sub-clinical liver injury to liver failure. This report illustrates the significance of appropriate education of the health care workers and the family and vigilant clinical monitoring throughout the duration of the therapy.

## Disclosure

This manuscript has been read and approved by all authors. This paper is unique and is not under consideration by any other publication and has not been published elsewhere. The authors and peer reviewers of this paper report no conflicts of interest. The authors confirm that they have permission to reproduce any copyrighted material. This work was exempt from approval by the Institutional Review Boards of both participating centers. Publication of this article was funded in part by the University of Florida Open-Access Publishing Fund.

## References

1. Pediatric Tuberculosis Collaborative Group. Targeted tuberculin skin testing and treatment of latent tuberculosis infection in children and adolescents. *Pediatrics*. 2004;114:1175–201.
2. Wu SS, Chao CS, Vargas JH, Sharp HL, Martin MG, McDiarmid SV, et al. Isoniazid-related hepatic failure in children: a survey of liver transplantation centers. *Transplantation*. 2007;84:173–9.
3. <http://www.cdc.gov/tb/publications/LTBI/pdf/TargetedLTBI05.pdf>.
4. Cillo U, Bassanello M, Vitale A, D'Antiga L, Zanusi G, Brolese A, et al. Isoniazid-related fulminant hepatic failure in a child: assessment of the native liver's early regeneration after auxiliary partial orthotopic liver transplant. *Transpl Int*. 2005;17:713–71.

5. Palusci VJ, O'hare D, Lawrence R. Hepatotoxicity and transaminase measurement during isoniazid chemoprophylaxis in children. *Pediatr Infect Dis J*. 1995;14:144–8.
6. Gal AA, Klatt EC. Fatal isoniazid hepatitis in a child. *Pediatr Infect Dis J*. 1986;5:490–1.
7. Lobato MN, Jereb JA, Starke JR. Unintended consequences: mandatory tuberculin skin testing and severe isoniazid hepatotoxicity. *Pediatrics*. 2008;121:e1732–3.
8. Vanderhoof JA, Ament ME. Fatal hepatic necrosis due to isoniazid chemoprophylaxis in a 15-year-old girl. *Pediatrics*. 1976;88:867–8.
9. Centers for Disease Control and Prevention. Severe isoniazid associated hepatitis: New York, 1991–1993. *MMWR Morb Mortal Wkly Rep*. 1993;42(28):545–7.
10. Nolan CM, Goldberg SV, Buskin SE. Hepatotoxicity associated with isoniazid preventive therapy: a 7-year survey from a public health tuberculosis clinic. *JAMA*. 1999;281(11):1014–8.
11. Israel HL, Gottlieb JE, Maddrey WC. Perspective: preventative isoniazid therapy and the liver. *Chest*. 1992;101:1298–301.
12. Moulding TS, Redeker AG, Kanel GC. Twenty isoniazid-associated deaths in one state. *Am Rev Respir Dis*. 1989;140:700–5.
13. Nakajo MM, Rao M, Steiner P. Incidence of hepatotoxicity in children receiving isoniazid chemoprophylaxis. *Pediatr Infect Dis J*. 1989;8:649–50.
14. Preziosi P. Isoniazid: metabolic aspects and toxicological correlates. *Curr Drug Metab*. 2007;8(8):839–51.
15. Huang YS, Chern HD, Su WJ, et al. Cytochrome P450 2E1 genotype and the susceptibility to antituberculosis drug-induced hepatitis. *Hepatology*. 2003;37:924–30.
16. O'brien RJ, Long MW, Cross FS, Lyle MA, Snider Jr DE. Hepatotoxicity from isoniazid and rifampin among children treated for tuberculosis. *Pediatrics*. 1983;72:491–9.
17. Pessayre D, Bentata M, Degott C, Nouel O, Miquet JP, Reuff B, et al. Isoniazid-rifampin fulminant hepatitis. *Gastroenterology*. 1977;72:284–9.

**Publish with Libertas Academica and every scientist working in your field can read your article**

*"I would like to say that this is the most author-friendly editing process I have experienced in over 150 publications. Thank you most sincerely."*

*"The communication between your staff and me has been terrific. Whenever progress is made with the manuscript, I receive notice. Quite honestly, I've never had such complete communication with a journal."*

*"LA is different, and hopefully represents a kind of scientific publication machinery that removes the hurdles from free flow of scientific thought."*

### Your paper will be:

- Available to your entire community free of charge
- Fairly and quickly peer reviewed
- Yours! You retain copyright

<http://www.la-press.com>