

CASE REPORT

OPEN ACCESS

Full open access to this and thousands of other papers at <http://www.la-press.com>.

Usefulness of Cardiac Computed Tomography in the Diagnosis of Prosthetic Coronary Artery Graft with Interposition Procedure

Ryotaro Wake, Shinichi Iwata, Masashi Nakagawa, Atsushi Doi, Kenichi Sugioka, Ryo Otsuka, Takeshi Hozumi, Yasuhiko Takemoto, Shoichi Ehara, Akihisa Hanatani, Takashi Muro and Minoru Yoshiyama

Department of Internal Medicine and Cardiology, Osaka City University Graduate School of Medicine, Osaka, Japan.
Correspondence author email: wake123aha@yahoo.co.jp

Abstract: An 80-year-old Japanese man was admitted with orthopnea and pitting edema of both lower legs. We diagnosed congestive heart failure (CHF) on the basis of a chest X-ray and an echocardiogram. An electrocardiogram showed a heart rate of 120 beats/min with atrial fibrillation rhythm (Af). The patient developed aortic valve failure and destruction of the base of right coronary artery (RCA) due to infectious endocarditis at 71 years of age. The patient underwent aortic valve replacement and coronary artery bypass grafting with an interposed graft with polyester vascular graft to RCA. The patient recovered from CHF after the 6 days of treatment with diuretics and verapamil. We confirmed the patency of coronary arteries and bypass grafts using a 64-slice cardiac computed tomography scan (CT) and diagnosed CHF due to Af. Here we describe the estimation of the prosthetic coronary artery graft patency with the interposition procedure using 64-slice cardiac CT.

Keywords: cardiac computed tomography angiography, prosthetic coronary artery graft, interposition procedure

Clinical Medicine Insights: Cardiology 2010:4 95–98

doi: 10.4137/CMC.S5806

This article is available from <http://www.la-press.com>.

© the author(s), publisher and licensee Libertas Academica Ltd.

This is an open access article. Unrestricted non-commercial use is permitted provided the original work is properly cited.

Case Report

An 80-year-old Japanese man was admitted to our hospital with orthopnea and pitting edema of both lower legs. A physical examination showed an irregular heart rate of 120 beats/min, a blood pressure of 130/80 mmHg, and a distended jugular vein. An electrocardiogram showed a heart rate of 120 beats/min with atrial fibrillation rhythm (Af). A chest X-ray showed slight cardiomegaly (Cardiothoracic ratio: 57%) and congestion. An echocardiogram showed the LV ejection fraction was 48%, and the LV distance was 55 mm in the diastolic phase and 37 mm in the systolic phase. LV diastolic dysfunction (early-to-atrial LV filling ratio [E/A]) based on diastolic Doppler mitral flow velocities was 77/- with an abnormal relaxation pattern. The inferior venacaval diameter was 21 mm with no respiratory variations. We diagnosed congestive heart failure (CHF) in this patient.

The patient's medical history is the followings. The patient underwent coronary artery bypass grafting

(CABG: left internal thoracic artery to left anterior descending coronary artery, a saphenous vein graft from the aorta to the first diagonal branch, and a radial artery graft from the aorta to the obtuse marginal coronary artery) for angina pectoris, and an aortic valve replacement (AVR: SJM25 A[®]) using the Bental procedure for aortic regurgitation at 70 years of age. At 71 years of age, the patient developed aortic valve failure and destruction of the base of right coronary artery (RCA) due to infectious endocarditis. He underwent re-AVR: Freestyle29 A[®] and CABG to RCA with an interposed graft with polyester vascular graft.¹

At 72 years of age, percutaneous coronary artery intervention and stenting for acute myocardial infarction in the proximal anastomosis between the prosthetic graft and the native coronary artery of RCA were performed.

After 6 days of treatment with diuretics and verapamil, he could walk about 100 m without dyspnea. Cardiomegaly and congestion was not

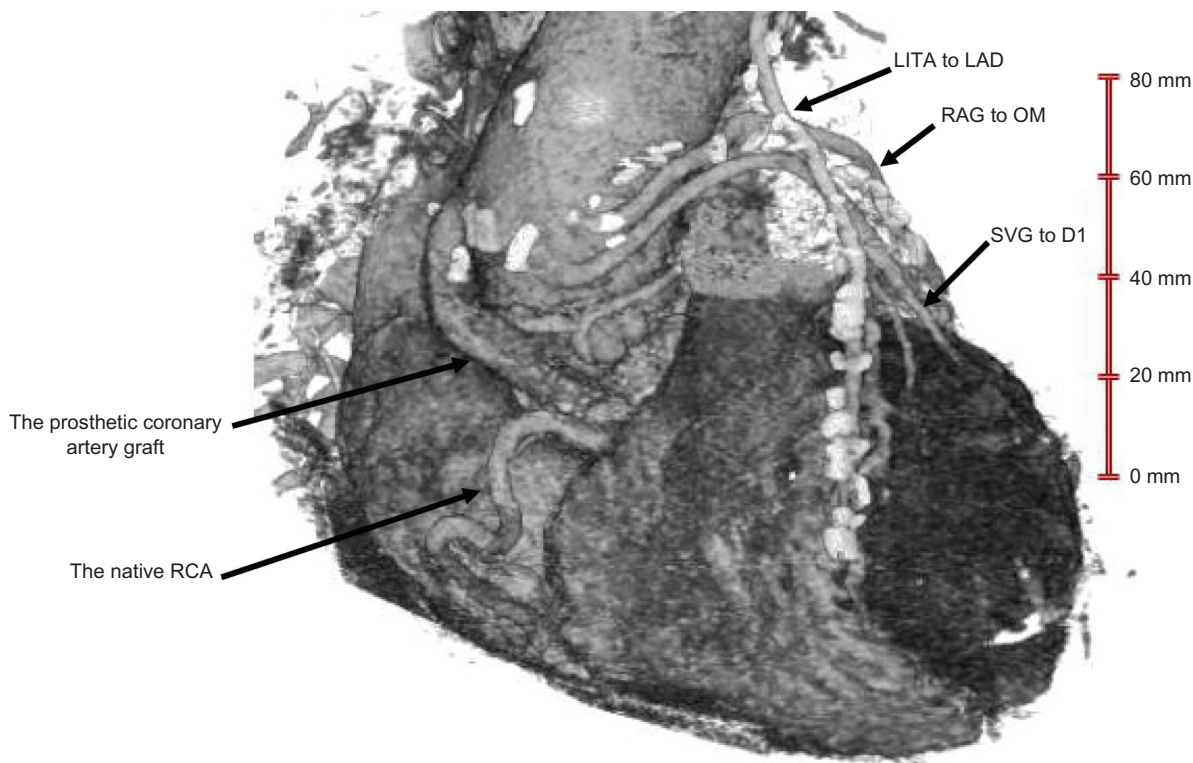


Figure 1. The right anterior view of the heart in the volume rendering image shows the right coronary artery (RCA) with interposition procedure (arrowhead). The abbreviations are shown in the lower part of the figure.

Abbreviations: D1, the first diagonal coronary artery; LAD, left anterior descending coronary artery; LITA, left internal thoracic artery; OM, obtuse marginal coronary artery; RAG, radial artery graft; RCA, right coronary artery; SVG, saphenous vein graft.

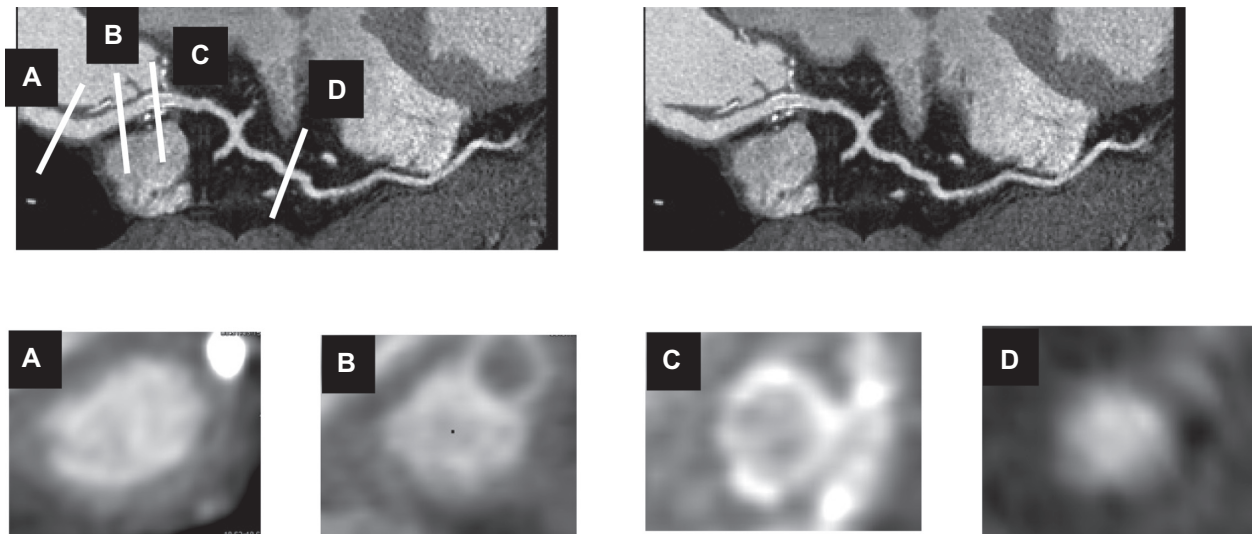


Figure 2. Panels A–D show the X-sectional images of the prosthetic coronary artery and native RCA with an interposition procedure.

evident on a chest X-ray or an echocardiogram. The patient recovered from CHF.

We performed a 64-slice cardiac computed tomography (CT) (SOMATOM Sensation 64[®]; Siemens Medical Solutions, Germany) with 85 ml of contrast medium (Iopamiron 370[®]; Bayer HealthCare, Berlin, Germany) after the patient's heart rate was regulated to less than 65 beats/min using 20 mg oral metoprolol 2 hours before the CT scan. The patient was given 0.6 mg nitroglycerin sublingually immediately before the scan.

We confirmed the patency of coronary arteries and bypass grafts (Figs. 1 and 2),² and we diagnosed the CHF was due to Af.

Thus, we report the assessment of a prosthetic vascular coronary graft patency with interposition procedure using the 64-slice cardiac CT.

Discussion

The diagnostic accuracy of cardiac CT angiography is useful to rule out the presence of coronary artery stenosis. Although the risk of adverse events associated with invasive coronary angiography is generally considered to be low, life-threatening complications can arise, including coronary artery dissection, arrhythmia, stroke, hemorrhage, myocardial infarction, and death.³

Cardiac CT angiography is established as an effective and non-invasive alternative to invasive coronary

angiography for ruling out obstructive coronary artery stenoses, because the negative predictive value of the coronary artery stenoses with cardiac CT angiography is 99%.^{2,4,5}

We report the usefulness of 64-slice cardiac CT in the assessment of prosthetic vascular coronary graft patency with the interposition procedure.

Disclosures

This manuscript has been read and approved by all authors. This paper is unique and is not under consideration by any other publication and has not been published elsewhere. The authors and peer reviewers of this paper report no conflicts of interest. The authors confirm that they have permission to reproduce any copyrighted material. Written consent was obtained from the patient for publication of this study.

References

1. Sauvage LR, Schloemer R, Wood SJ, Logan G. Successful interposition synthetic graft between aorta and right coronary artery. Angiographic follow-up to sixteen months. *J Thorac Cardiovasc Surg.* 1976;72: 418–21.
2. Pache G, Saueressig U, Frydrychowicz A, et al. Initial experience with 64-slice cardiac CT: non-invasive visualization of coronary artery bypass grafts. *Eur Heart J.* 2006;27:976–80.
3. Bashore TM, Bates ER, Berger PB, et al. American College of Cardiology/Society for Cardiac Angiography and Interventions Clinical Expert Consensus Document on cardiac catheterization laboratory standards. A report of the American College of Cardiology Task Force on Clinical Expert Consensus Documents. *J Am Coll Cardiol.* 2001;37:2170–214.



4. Budoff MJ, Dowe D, Jollis JG, et al. Diagnostic performance of 64-multidetector row coronary computed tomographic angiography for evaluation of coronary artery stenosis in individuals without known coronary artery disease: results from the prospective multicenter ACCURACY (Assessment by Coronary Computed Tomographic Angiography of Individuals Undergoing Invasive Coronary Angiography) trial. *J Am Coll Cardiol*. 2008;52:1724–32.
5. Miller JM, Rochitte CE, Dewey M, et al. Diagnostic performance of coronary angiography by 64-row CT. *N Engl J Med*. 2008;359:2324–36.

Publish with Libertas Academica and every scientist working in your field can read your article

“I would like to say that this is the most author-friendly editing process I have experienced in over 150 publications. Thank you most sincerely.”

“The communication between your staff and me has been terrific. Whenever progress is made with the manuscript, I receive notice. Quite honestly, I’ve never had such complete communication with a journal.”

“LA is different, and hopefully represents a kind of scientific publication machinery that removes the hurdles from free flow of scientific thought.”

Your paper will be:

- Available to your entire community free of charge
- Fairly and quickly peer reviewed
- Yours! You retain copyright

<http://www.la-press.com>