

ORIGINAL RESEARCH

OPEN ACCESS

Full open access to this and thousands of other papers at <http://www.la-press.com>.

Subaortic (Type 6) Muscular Band—Innocent Bystander or Pathologic Structure?

J Ker

Department of Physiology, University of Pretoria, Gesina, Pretoria, South Africa.
Correspondence author email: jker@wol.co.za

Abstract: Intraventricular tendons are structures that was identified more than a hundred years ago. It has been suggested that they represent intracavitary radiations of the bundle of His and that they may be an isolated finding or be associated with structural cardiac abnormalities.

Loukas et al divided these structures into five categories and recently a sixth type have been added.

Various physiological disturbances have been observed due to the sixth type of tendon, such as ST segment elevation and right bundle branch block. It has been noted that this peculiar structure appears too thick to be called a tendon, thus the term band.

This retrospective analysis analyzed the incidence of the thick, subaortic (type 6) muscular band in a cardiovascular clinic.

Keywords: subaortic, band, type 6

Clinical Medicine Insights: Cardiology 2010:4 69–71

This article is available from <http://www.la-press.com>.

© the author(s), publisher and licensee Libertas Academica Ltd.

This is an open access article. Unrestricted non-commercial use is permitted provided the original work is properly cited.

Introduction

Intraventricular tendons were first observed 115 years ago.¹ They are usually thin, fibrous or fibromuscular structures that traverse the left ventricular cavity.² They may be single or multiple and have no connection to the valvular cusps.²

False tendons can be an isolated finding or can be associated with cardiac abnormalities.³

Loukas et al⁴ examined 200 formalin fixed, adult hearts and divided false tendons into five categories: In type I the false tendon is located between the posteromedial papillary muscle and the ventricular septum. In type II the false tendon is located between the two papillary muscles. In type III the false tendon is located between the anterolateral papillary muscle and the ventricular septum. In type IV the false tendon is located between the ventricular septum and the free wall. In type V the false tendons appear weblike and have three or more points of insertion.

After careful histological examination Abdulla et al³ suggested that false tendons may be intracavitary radiations of the bundle of His and that their clinical significance may be more relevant than previously believed and merits further study.

Recently, various physiological effects due to a newly observed thick, subaortic muscular band have been described.^{5–7}

The purpose of this study was to describe the incidence of this peculiar new type of muscular band in a cardiovascular clinic.

Methods

This study was a retrospective analysis. A total of 4900 adult echocardiograms, performed between 2004 and 2010 for various clinical indications—ranging from hypertension to cardiac murmurs and dyspnoea—were reviewed and analyzed for the presence of a left ventricular muscular band in the subaortic position.

Results

A total of 376 adult echocardiograms clearly demonstrated the presence of a muscular structure, located between the left ventricular inferior wall and the subaortic interventricular septum (see Figure 1 and 2 and movie clip 1 and 2). In all of these cases a striking local ventricular hypertrophic response was present at the site of septal implantation. In some of these cases the local hypertrophic response even mimics

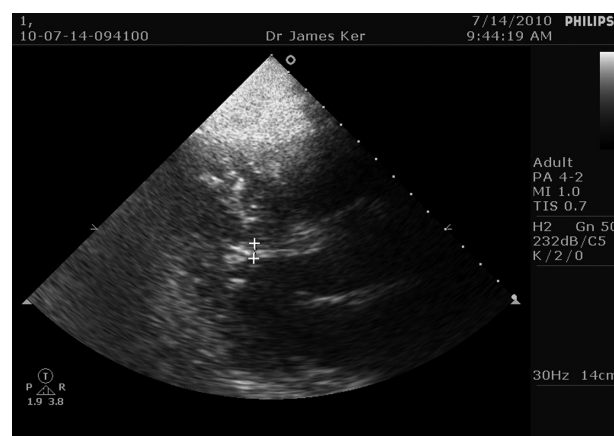

Figure 1 Parasternal, long-axis echocardiographical image, depicting a thick subaortic, muscular band, marked with X.

the echocardiographical appearance of hypertrophic cardiomyopathy⁶ (see movie clip 1).

Discussion

A peculiar muscular structure, too thick in appearance to be called a tendon, extending between the subaortic portion of the interventricular septum and the inferior left ventricular wall is identified in this study. A striking feature is a localized area of ventricular hypertrophy at the site of subaortic implantation of the muscular structure.

Among these 376 patients with the muscular subaortic band present, the following physiological effects have been observed: ST-segment elevation of the anterior electrocardiographic leads, mimicking acute myocardial infarction,⁴ echocardiographical mimicking of hypertrophic cardiomyopathy⁵ and right bundle branch block.⁶

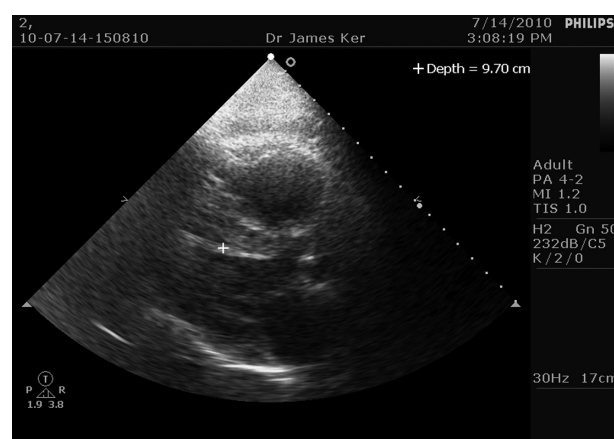


Figure 2 Another example of a thick subaortic muscular band, marked with X.



It has been proposed before that this muscular, subaortic band may represent a sixth type of ventricular false tendon.⁸ The current clinical implication of the presence of this peculiar intracardiac structure is that it may mimic cardiac disease, such as myocardial infarction or Brugada syndrome in the case of ST segment elevation,⁵ it may lead to the erroneous diagnosis of hypertrophic cardiomyopathy if the echocardiographer is not vigilant⁶ and recently it has been described that a third type of right bundle branch block may result due to the presence of such a subaortic muscular band.⁷

Disclosures

This manuscript has been read and approved by the author. This paper is unique and is not under consideration by any other publication and has not been published elsewhere. The author and peer reviewers of this paper report no conflicts of interest. The author confirms that they have permission to reproduce any copyrighted material.

References

1. Turner W. A human heart with moderator band in left ventricle. *J Anat Physiol*. 1893;27:19.
2. Kervancioglu M, Ozbag D, Kervancioglu P, et al. Echocardiographic and morphologic examination of left ventricular false tendons in human and animal hearts. *Clinical Anatomy*. 2003;16(5):389–95.
3. Abdulla AK, Frustaci A, Martinez JE, Florio RA, Somerville J, Olsen EGJ. Echocardiography and pathology of left ventricular false tendons. *Chest*. 1990;98:129–32.
4. Loukas M, Louis RG, Black B, Pham D, Fudalej M, Sharkees M. False tendons: An endoscopic cadaveric approach. *Clinical Anatomy*. 2007;20(2):163–9.
5. Ker J. Sub aortic tendon induced ST segment elevation—a new echo electrocardiographic phenomenon? *Cardiovascular Ultrasound*. 2009;7:13.
6. Ker J. The sub aortic tendon as a mimic of hypertrophic cardiomyopathy. *Cardiovascular Ultrasound*. 2009;7:31.
7. Ker J. Structural causes of right bundle branch block—time for a closer look? *The Open Cardiovascular Medicine Journal* 2010;4:105–9.
8. Ker J. False tendon induced subaortic hypertrophy—a new variant of hypertrophic cardiomyopathy. In: *Cardiomyopathies: Causes, Effects and Treatment*. Edited by: Bruno PH, Giordano MT. Nova Science Publishers; 2008.

Publish with Libertas Academica and every scientist working in your field can read your article

“I would like to say that this is the most author-friendly editing process I have experienced in over 150 publications. Thank you most sincerely.”

“The communication between your staff and me has been terrific. Whenever progress is made with the manuscript, I receive notice. Quite honestly, I’ve never had such complete communication with a journal.”

“LA is different, and hopefully represents a kind of scientific publication machinery that removes the hurdles from free flow of scientific thought.”

Your paper will be:

- Available to your entire community free of charge
- Fairly and quickly peer reviewed
- Yours! You retain copyright

<http://www.la-press.com>