Breast Cancer: Basic and Clinical Research

ORIGINAL RESEARCH

Detection of Provasopressin in Invasive and Non-invasive (DCIS) Human Breast Cancer Using a Monoclonal Antibody Directed Against the C-terminus (MAG1)

Brendan P. Keegan, Vincent A. Memoli, Wendy A. Wells and William G. North

Department of Physiology (B.P.K., W.G.N.) and Pathology (V.A.M., W.A.W), Dartmouth Medical School, Lebanon, New Hampshire 03756, USA. Email: william.g.north@dartmouth.edu

Abstract: The provasopressin protein (proAVP) is expressed by invasive breast cancer and non-invasive breast cancer, or ductal carcinoma in situ (DCIS). Here we demonstrate the ability of the monoclonal antibody MAG1 directed against the C-terminal end of proAVP to identify proAVP in all cases examined of human invasive cancer and DCIS (35 and 26, respectively). Tissues were chosen to represent a relevant variation in tumor type, grade, patient age, and menopausal status. By comparison, there was 65% positive staining for estrogen receptor, 61% for progesterone receptor, 67% for nuclear p53, and 39% for c-Erb-B2 with the invasive breast cancer sections. Reaction with the normal tissue types examined (67) was restricted to the vasopressinergic magnocellular neurons of the hypothalamus, where provasopressin is normally produced, and the posterior pituitary, where these neurons terminate. The breast epithelial tissue sections on the tissue microarray did not react with MAG1. Previously, we demonstrated that polyclonal antibodies to proAVP detected that protein in all breast cancer samples examined, but there was no reaction with breast tissue containing fibrocystic disease. The results presented here not only expand upon those earlier results, but they also demonstrate the specificity and effectiveness of what may be considered a more clinically-relevant agent. Thus, proAVP appears to be an attractive target for the detection of invasive breast cancer and DCIS, and these results suggest that MAG1 may be a beneficial tool for use in the development of such strategies.

Keywords: invasive breast cancer, ductal carcinoma in situ (DCIS), vasopressin, provasopressin, monoclonal antibody

Breast Cancer: Basic and Clinical Research 2010:4 15–22

This article is available from http://www.la-press.com.

Introduction

The arginine vasopressin (AVP) gene is expressed in small-cell lung cancer (SCLC) and breast cancer cells, while there appears to be a low incidence of its expression in non-neuroendocrine tumors.[1] In normal tissues, AVP expression is largely restricted to the hypothalamus, where the provasopressin (proAVP) protein is packaged into secretory vesicles and undergoes enzymatic modification to generate AVP, vasopressin-associated neurophysin (VP-NP), and vasopressin-associated glycopeptide (VAG).[2] AVP can have a proliferative effect on cancer cells and it appears that the production of AVP by these cells aids in tumor growth and survival.[3–5] VP-NP is important for the proper intracellular transport and processing of proAVP.[6–8] The VAG region contains a conserved glycosylation consensus sequence,[9–11] which has been shown to be important for proAVP folding,[12] but not essential for proper processing.[13] Previously, we described a monoclonal antibody (mAb) directed against the VAG region of human proAVP, designated MAG1, that reacted with proAVP forms in breast cancer and SCLC cultured cell lysates by Western blot analysis.[5,14,15] It also displayed immunoreactivity with SCLC tissue, but not with normal lung tissues, by immunohistochemical analysis.[14] Earlier studies performed using polyclonal antibodies raised against AVP and VAG indicate that invasive breast cancer and non-invasive breast cancer, or ductal carcinoma in situ (DCIS), contain proAVP products, but these products are not found in breast tissue with fibrocystic disease.[16,17] Therefore, we wished to determine the specificity and effectiveness of a single mAb (MAG1) for the detection of proAVP in breast cancer and DCIS tissues by immunohistochemical analysis, since it may be considered a more clinically-relevant agent. We examined in-house tissue sections from 35 invasive breast cancer and 26 DCIS cases with the MAG1 mAb, and compared this reactivity with that seen in normal tissue specimens on commercially available tissue microarrays, representing 66 different tissue types.

Materials and Methods

Antibodies

The MAG1 mAb is a mouse antibody of subclass IgG1 directed against the C-terminal 18 amino acid residues of the proAVP protein. This sequence is located at the end of the VAG region of the protein, but does not contain the glycosylation site. Production and purification of the MAG1 mAb has been described elsewhere.[14] The isotype-matched control antibody, MOPC21, was obtained from MP Biomedicals (Irvine, CA).

Tissues

Formalin-fixed biopsy specimens from 61 patients (35 invasive breast cancer and 26 DCIS cases) were obtained from archival tissue blocks from the Department of Pathology at the Dartmouth Hitchcock Medical Center (Lebanon, NH). Information about the tumor grade, patient age, and other details are presented in Tables 1 and 2. Tissues were chosen to represent a clinically relevant variation in disease types, grade, and menopausal status. The invasive breast cancer tissues that were selected had undergone diagnostic immunohistochemical evaluation for estrogen receptor, progesterone receptor, nuclear p53, and ErbB2 expression. Sections from a formalin-fixed segment of anterior human hypothalamus that was obtained at autopsy were used as positive controls. The normal tissue microarrays CHTN2002N1 and CHTN2002X were obtained from the Cooperative Human Tissue Network (University of Virginia Health System, Charlottesville, VA). Detailed information of these microarrays can be obtained at: http://faculty.virginia.edu/chtn-tma/index.html. There are a combined total of 66 human tissue types represented on the microarrays, with a spot size of 0.6 mm (CHTN2002N1) or 2 mm (CHTN2002X) at 4 μM thickness.

Immunohistochemistry

All steps were performed at ambient temperature unless otherwise stated. Tissue sections (4–6 μM) and microarrays were deparaffinized by heat exposure (60 °C for 10 min), washed in xylene (2 × 5 min), and rehydrated by washing (2 × 5 min) in descending concentrations of ethanol (100%, 95%, 70%). After washing with PBS (2 × 5 min), the tissues were subjected to antigen retrieval by incubation with trypsin or 0.01 M sodium citrate (pH 8.5) for 30 min at 80 °C.[14,18] Trypsin was removed by washing with 95% ethanol (1 × 1 min), followed by PBS (1 × 10 min). Both antigen retrieval procedures were equally effective, however the citrate treatment resulted in lower background staining. After PBS washes (2 × 5 min), endogenous peroxidase activity

Table 1. Invasive breast cancer tissue specimens examined.

Tumor Grade[a]	Grade[b]	Menopausal Status[c]	Ini/Rec[d]	ER/PR[e]	p53[f]	c-Erb-B2[g]
IDC	H	Pre		neg/neg	pos	pos
IDC	H	Pre	Ini	neg/neg		
IDC	H	Pre	Ini	neg/neg		neg
IDC	H	Post		neg/neg	pos	neg
IDC	H	Post	Ini	pos/neg	pos	pos
IDC	H	Post	Ini	pos/pos		neg
IDC	H	Post	Ini	neg/neg		
IDC	H	Post	Ini	neg/neg		neg
IDC	H	MALE				
IDC	I	Post	Ini	pos/pos	pos	pos
IDC	I	Post	Ini	neg/pos	pos	pos
IDC	I	Post	Ini	pos/pos		neg
IDC	I	Post	Ini	pos/pos	pos	pos
IDC	I	Post	Ini	pos/pos	neg	pos
IDC	I	MALE	Ini	pos/pos		
IDC	I	Post	Rec	pos/neg	pos	
IDC	I	Post	Rec	neg/pos		
IDC	I	Post	Rec	neg/neg	pos	pos
IDC	L	Post	Ini	neg/neg	pos	neg
IDC	L	Post	Ini	pos/neg	neg	neg
IDC	L	Post	Ini	pos/pos	pos	neg
IDC	L	Post	Ini	pos/pos		
IDC	L	Post	Rec	pos/pos	neg	neg
IDC	L	Post	Ini	pos/pos	pos	neg
IDC		Post	Ini	pos/neg	neg	neg
IDC (apocrine)	n/a[h]	Post	Ini	neg/equivocal		pos
IDC (colloid)	n/a	Post	Ini	pos/pos	pos	neg
IDC (colloid)	n/a	Pre	Ini	pos/pos	pos	neg
IDC (cribiform)	n/a	Post	Ini	pos/pos	neg	pos
IDC (medullary)	n/a	Post	Ini	neg/neg	neg	pos
ILC	n/a	Post	Ini	pos/pos	neg	neg
ILC	n/a	Post	Ini	pos/pos	pos	neg
ILC	n/a	Post	Rec	pos/pos	pos	pos
ILC	n/a	Post	Ini	pos/pos	neg	neg
ILC	n/a	Post	Ini	pos/pos	pos	neg

[a]Tumor Type: (IDC) infiltrating ductal carcinoma, special types are indicated in parenthesis, (ILC) infiltrating lobular carcinoma.
[b]Grade: (H) high grade, (I) intermediate grade, (L) low grade.
[c]Menopausal status: (Pre) premenopausal, (Post) postmenopausal, (MALE) male subjects.
[d]Ini/Rec: Initial or Recurrent disease.
[e]ER/PR: estrogen and progesterone receptor (Positive indicates greater than 15% staining of cancer cells, equivocal indicates 1%–15% staining, and negative is no staining).
[f]p53: nuclear p53 staining.
[g]c-Erb-B2: Positive indicates 2+ or 3+ staining negative indicates 0 or 1+ staining according to HercepTest guidelines.
[h]n/a: not applicable.
Note: Blank spaces indicate where information was not available.

Table 2. DCIS tissue specimens examined.

DCIS Grade[a]	Menopausal Status[b]
H	Pre
H	Pre
H	Pre
H	Post
H	Post
H	Post
H	Post
H	Post
H	Post
H	Post
I	Pre
I	Pre
I	Pre
I	Pre
I	Pre
I	Pre
I	Pre
I	Post
I	Post
I	Post
I	Post
I	Post
I	Post
I	Post
L	Pre
	Post

[a]DCIS Grade: (H) high grade, (I) intermediate grade, (L) low grade.
[b]Menopausal status: (Pre) premenopausal, (Post) postmenopausal.
Note: Blank spaces indicate where information was not available.

was quenched by incubation in 3% hydrogen peroxide for 5 min. Components of the Vectastain Elite ABC Kit (Vector Laboratories, Burlingame CA) were used for subsequent steps, following the manufacture's instructions. Briefly, tissue sections were blocked with 10% normal horse serum (10–20 min), rinsed and incubated in PBS containing MAG1 or IgG1 isotype control mAb (MP Biomedicals (Irvine, CA). The majority of the invasive breast cancer and DCIS specimens were incubated overnight at 4 °C with 0.25 µg/ml of antibody in PBS containing 1.5% horse serum. The normal tissue microarrays were incubated at ambient temperature with 1 µg/ml of antibody in PBS containing 0.4 M NaCl and 1.5% horse serum. These methods yielded identical results as indicated from the staining of replicate invasive breast cancer, DCIS, and human hypothalamus tissue sections that were included in the processing as positive controls for the microarrays. Antibody specificity was assessed on the invasive breast cancer and DCIS tissue sections by incubating them with antigen-blocked (10 µg/ml peptide) MAG1. After incubation with primary antibodies, the tissue sections were washed with PBS (3 × 5 min), and then reacted sequentially with biotinylated goat anti-mouse IgG and ABC reagent. PBS washes (3 × 5 min) were performed in between each step. Staining was achieved using ImmunoPure Metal Enhanced DAB Substrate Kit (Pierce, Rockford, IL), with typical incubation times from 3–5 min. Tissues were then counterstained with Mayer's hematoxylin (Sigma, St. Louis MO), dehydrated in ascending concentrations of ethanol, washed in xylene, and cover-slipped using Permount mounting medium (Fisher Scientific, Pittsburg PA). The staining of the sections and microarrays was recorded using a Micropublisher camera (Qimaging, Burnaby, British Columbia, Canada) connected to a BX51 or a BX40 microscope (Olympus, Melville, NY).

Results

MAG1 was found to react with all 35 invasive breast cancer and all 26 DCIS cases examined, regardless of patient age, sex, tumor type, grade, or the status of the other biomarkers that were tested for (Tables 1 and 2). Of the invasive breast cancer cases, there were 30 (86%) infiltrating ductal carcinomas (IDC) and 5 (14%) infiltrating lobular carcinomas (ILC) used in this study. Of the IDC cases, 9 were high grade (30%), 9 were intermediate grade (30%), 6 were low grade (20%), and 5 were special-type (17%), as indicated in Table 1. Special-type IDC's and ILC's are not routinely assigned a tumor grade. The age of the patients ranged from 39 to 92 years with 1 patient in her 30's (3%), 4 in their 40's (11%), 7 in their 50's (20%), 10 in their 60's (29%), 8 in their 70's (23%), 2 in their 80's (6%), and 2 in their 90's (6%). Two of the patients were males (6%). Twenty-nine of the female patients were recorded as postmenopausal (88%) and 4 were recorded as premenopausal (12%). All of the tissues were from lesions at the

primary site. Five of the invasive breast cancers, for which there was data, represented recurrent disease (16%). Eighteen tissues were from tumors that were both estrogen and progesterone receptor (ER/PR) positive. Twenty-two of the 34 sections that were screened for ER were positive (65%), and twenty were positive for PR (61%), 7 were ER/PR negative and 6 were of a mixed receptor profile (approximately 20% each). Nuclear p53 staining was present in 16 of the 24 cases tested (67%). Intense membranous c-Erb-B2 immunostaining was present in 11 of the 28 (39%) tissue sections examined (scores 2+ and 3+), while staining that rated 0 or 1+ according to the HercepTest criteria are listed as negative. Grading information was available for twenty-five of the tenty-six DCIS cases. Ten were high grade (40%), 14 were intermediate grade (56%), and 1 was low grade (4%). Fifteen of the tissue sections were from postmenopausal women (60%) and 11 were from premenopausal women (44%). The age of the DCIS patients ranged from 39 to 75 years with 2 patients in their 30's (8%), 11 in their 40's (42%), 4 in their 50's (15%), 4 in their 60's (15%), and 1 in her 70's (4%).

MAG1 reactivity with invasive breast cancer and DCIS tissue was blocked by co-incubation with excess synthetic antigen (Fig. 1), and MOPC21 isotype control displayed no reactivity with these tissues (not shown). Breast tissue that appeared to be normal and tissue containing benign fibrocystic disease that was adjacent to the invasive breast cancer and DCIS cells was also found to react with MAG1. This staining however, was consistently variable and less intense in contrast to that observed in the invasive breast cancer and DCIS tissues.

MAG1 and MOPC21 displayed a complete lack of immunoreactivity with 4 samples of normal breast epithelium tissue on the normal tissue microarrays (Fig. 2). Of the 318 different specimens representing 66 tissue types on the microarrays, only the 2 posterior pituitary specimens were found to react with MAG1.

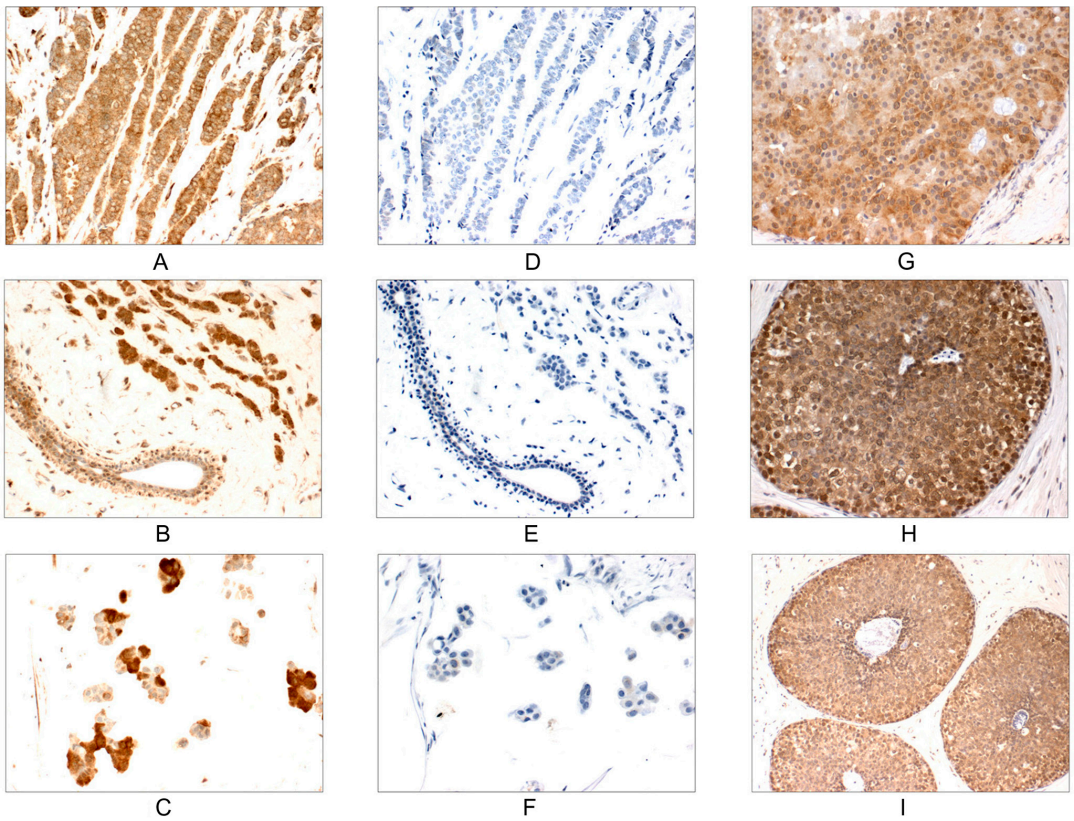

Figure 1. MAG1 immunoreactivity was observed with all cases of breast cancer examined (magnification × 10). For invasive breast cancer, the figures show positive staining of sections from **A**) infiltrating ductal carcinoma, **B**) infiltrating lobular carcinoma, with a normal lobe present **C**) mucinous carcinoma cases. Co-incubation of MAG1 with synthetic peptide antigen blocked the MAG1 immunodetection of proAVP in these specimens **D–F**). For DCIS, the figures show positive staining of sections from **G**) cribiform low grade, **H**) intermediate grade, and **I**) comedo high grade cases. Co-incubation of MAG1 with synthetic peptide antigen blocked MAG1 immunodetection of proAVP in these specimens (not shown).

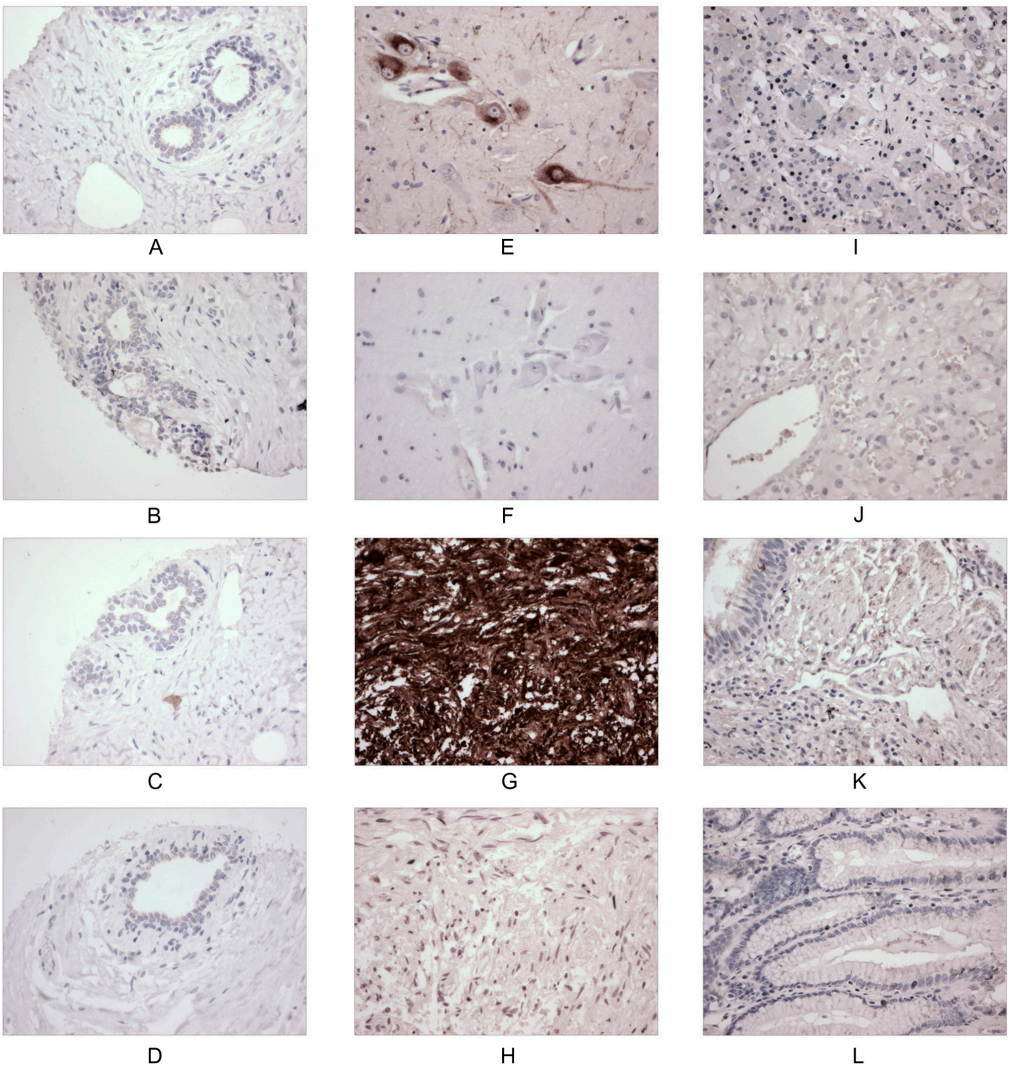

Figure 2. MAG1 immunoreactivity with normal tissue. The MOPC21 mAb was used as an isotype control. Breast epithelium stained with MAG1 **A**–**D**). Human hypothalamus stained with **E**) MAG1 **F**) or MOPC21. Posterior pituitary stained with **G**) MAG1 or **H**) MOPC21. Anterior pituitary **I**), Corpus luteum **J**), bronchus epithelium **K**), and gastric mucosa **L**) stained with MAG1. Magnification × 10 **A**–**D**, **I**–**L**), and × 20 **E**–**H**).

This was anticipated due to the presence of vasopressinergic neuron storage terminals. Thus, the posterior pituitary sections served as an internal positive control for the microarrays. Staining of magnocellular neurons in sections of hypothalamus, localized to supraoptic nucleus region, displayed strong immunoreactivity with MAG1, but not with MOPC21. This staining was not evident in tissues from other regions of the brain or with some of the other tissues reported to express the vasopressin gene (see below).

Discussion

It has been known for some time that certain cancers can express neuropeptides, including AVP. The majority of studies concerning AVP expression by cancer cells have focused on SCLC, while far fewer have examined its expression by other types of cancer cells. The MAG1 mAb reacts with SCLC cells, while reactivity with the corresponding normal tissue was negative.[14,15] MAG1 also reacts with cultured breast cancer cells,[5] and we have demonstrated that proAVP is expressed by breast cancer and DCIS tissue.[16,17] Those studies, however, were performed using polyclonal antibodies (pAb) raised against AVP and VAG or a mAb against vasopressin-associated neurophysin. The anti-VAG and anti-AVP pAbs were able to detect proAVP in all of the breast cancer tissues screened, but a monoclonal antibody to neurophysin reacted with only one of the tissues tested.[16] Since mAbs might be considered a more clinically-relevant than pAbs because of their

homogeneity, production, and lack of irrelevant antibodies in the preparation, we undertook an immunohistochemical analysis of tissue sections from 35 invasive breast cancer cases, 26 DCIS cases, and 67 various normal tissue types, including human hypothalamus, with the MAG1 mAb. We found that MAG1 mAb recognized proAVP in all of the invasive breast cancer and DCIS cases examined. The invasive breast cancer specimens were tested for the expression of other common biomarkers, and it was found that 65% were positive for ER, 61% for PR, 67% for nuclear p53, and 39% for c-Erb-B2. Thus, proAVP was detected by MAG1 in all invasive breast cancer specimens, including ER-positive and ER-negative cases. These results demonstrate the ability of the MAG1 mAb to stain breast cancers regardless of the status of common biomarkers, disease type, grade, or the age and sex of the patient. These results are supported by earlier findings using polyclonal antibodies against proAVP that show that AVP was expressed in all invasive breast cancer and DCIS cases examined.[16,17] Surprisingly, we found that MAG1 reacted with some of the non-cancerous tissue adjacent to the breast cancer or DCIS cells. Recent work indicates that genetic changes that alter that expression of proteins, such as Fas ligand (FasL), occur prior to morphological changes in peritumoral breast tissue.[19] Thus, it is possible that the expression of neuropeptides, such as AVP expression, is associated with malignant transformation.

In hypothalamus tissue sections, proAVP expression was strictly limited to regions containing vasopressinergic neurons, where it is normally produced. On normal tissue microarrays, MAG1 immunoreactivity was observed only with specimens of posterior pituitary, where many of the vasopressinergic neurons terminate. There was no evidence of proAVP expression with the remaining human tissue specimens, representing 65 various tissue types, contained on the microarray. The presence of AVP-related protein products in select cells of various tissues such as the thymus, spleen, and of the gastrointestinal system has been demonstrated.[20–22] In other tissues where AVP-related immunoreactivity has been found, such as the testes, adrenal gland, and corpus luteum, there is question as to the whether the hormone is actually synthesized at that site.[23–26] Although samples of these tissues were represented on the microarrays, MAG1 displayed no discernable immunoreactivty with them. In the thymus tissue, the predominant form of neurophysin present is oxytocin-related neurophysin, which suggests an inability to discriminate from vasopressin-related neurophysin in such cases. Under the staining conditions described here, MAG1 showed clear positive staining for the posterior pituitary samples on the microarrays and hypothalamus sections. Pulmonary neuroendocrine cells in the bronchioles of normal lung tissue sections were also found to stain positive with MAG1 mAb,[14] however none were evident on the microarrays. These differences are most likely due to the absence of those few neuroendocrine-type cells from the small region of the tissue specimens present on the microarrays, but it is clear that proAVP expression is not abundant in the vast majority on normal tissues. In conjunction with our previous reports, proAVP has been detected in all of the 62 invasive breast cancer and 47 DCIS cases examined by immunohistochemical analysis,[16,17] thus it appears that the AVP gene is likely to be expressed by most, if not all invasive breast cancer and DCIS cells.

There appears to be a very low incidence of proAVP expression in a wide variety of normal tissues, to include breast. Recently, we demonstrated that proAVP is produced by cultured breast cancer cells, proAVP products can be secreted from them, and AVP can promote their growth. Activation of the phosphatidylinositol 3-kinase pathway is critical for the neoplastic transformation of breast cells[27] and thus the initiation of AVP gene activation may be a contributing factor to this event. While this remains to be seen, the fact that proAVP is present in all of the samples we have examined to date indicates that it is an attractive target for the development of detection and treatment strategies for breast cancer, and that MAG1 should prove to be useful in this respect.

Acknowledgments

We are indebted to Maudine Waterman, Andrea Osborne, and Alison North for their technical support, and to assistance from the Dartmouth Medical School Research Pathology Services. This work was supported by grants to William G. North (PHS CA 92506 and DK 07508), though an NCI core grant to the Norris Cotton Cancer Center (CA 23108), and by DOD fellowship to Brendan P. Keegan (DAMD 17-02-1-0365). These authors (B.P.K., W.G.N) have applied

for patent protection of MAG1 and are affiliated with a company involved in its further development.

Disclosures

This manuscript has been read and approved by all authors. This paper is unique and is not under consideration by any other publication and has not been published elsewhere. The peer reviewers of this paper report no conflicts of interest. The authors confirm that they have permission to reproduce any copyrighted material.

References

1. Friedmann AS, Memoli VA, North WG. Vasopressin and oxytocin production by non-neuroendocrine lung carcinomas: an apparent low incidence of gene expression. *Cancer Lett*. 1993;75:79–85.
2. North WG, Valtin H, Cheng S, Hardy GR. The neurophysins: production and turnover. *Prog Brain Res*. 1983;60:217–25.
3. Seckl MJ, Higgins T, Widmer F, Rozengurt E. [D-Arg1,D-Trp5,7,9, Leu11]substance P: a novel potent inhibitor of signal transduction and growth in vitro and in vivo in small cell lung cancer cells. *Cancer Res*. 1997;57:51–4.
4. Pequeux C, Keegan BP, Hagelstein MT, Geenen V, Legros JJ, North WG. Oxytocin- and vasopressin-induced growth of human small-cell lung cancer is mediated by the mitogen-activated protein kinase pathway. *Endocr Relat Cancer*. 2004;11:871–85.
5. Keegan BP, Akerman BL, Pequeux C, North WG. Provasopressin expression by breast cancer cells: Implications for growth and novel treatment strategies. *Breast Cancer Res Treat*. 2006;95:265–77.
6. de Bree FM. Trafficking of the vasopressin and oxytocin prohormone through the regulated secretory pathway. *J Neuroendocrinol.* 2000;12:589–94.
7. de Bree FM, Knight D, Howell L, Murphy D. Sorting of the vasopressin prohormone into the regulated secretory pathway. *FEBS Lett*. 2000;475: 175–80.
8. de Bree FM, Van Der Kleij AA, Nijenhuis M, Zalm R, Murphy D, Burbach JP. The Hormone Domain of the Vasopressin Prohormone is Required for the Correct Prohormone Trafficking Through the Secretory Pathway. *J Neuroendocrinol*. 2003;15:1156–63.
9. Sausville E, Carney D, Battey J. The human vasopressin gene is linked to the oxytocin gene and is selectively expressed in a cultured lung cancer cell line. *J Biol Chem*. 1985;260:10236–41.
10. Schmale H, Heinsohn S, Richter D. Structural organization of the rat gene for the arginine vasopressin-neurophysin precursor. *Embo J*. 1983;2:763–7.
11. Chauvet MT, Chauvet J, Acher R. The glycopeptide domain of the rat vasopressin precursor. *FEBS Lett*. 1983;163:257–60.
12. Barat C, Simpson L, Breslow E. Properties of human vasopressin precursor constructs: inefficient monomer folding in the absence of copeptin as a potential contributor to diabetes insipidus. *Biochemistry*. 2004;43:8191–203.
13. Iwasaki Y, Oiso Y, Saito H, Majzoub JA. Effects of various mutations in the neurophysin/glycopeptide portion of the vasopressin gene on vasopressin expression in vitro. *Tohoku J Exp Med*. 2000;191:187–202.
14. Keegan BP, Memoli VA, North WG. Targeting the neurophysin-related cell surface antigen on small cell lung cancer cells using a monoclonal antibody against the glycopeptide region (MAG-1) of provasopressin. *Mol Cancer Ther*. 2002;1:1153–9.
15. North WG, Memoli VA, Keegan BP. Immunohistochemical Identification of NRSA on SCLC using a Monoclonal Antibody (MAG-1) that recognizes the Carboxyl Terminus of Provasopressin. *Appl Immunohistochem Mol Morphol*. 2005;13:363–6.
16. North WG, Pai S, Friedmann A, Yu X, Fay M, Memoli V. Vasopressin gene related products are markers of human breast cancer [published erratum appears in *Breast Cancer Res Treat.* 1995;36(1):99]. *Breast Cancer Res Treat*. 1995;34:229–35.
17. North WG, Wells W, Fay MJ, Mathew RS, Donnelly EM, Memoli VA. Immunohistochemical evaluation of vasopressin expression in breast fibrocystic disease and ductal carcinoma in situ (DCIS). *Endocr Pathol*. 2003;14:257–62.
18. Jiao Y, Sun Z, Lee T, et al. A simple and sensitive antigen retrieval method for free-floating and slide-mounted tissue sections. *J Neurosci Methods*. 1999;93:149–62.
19. Mottolese M, Nadasi EA, Botti C, et al. Phenotypic changes of p53, HER2, and FAS system in multiple normal tissues surrounding breast cancer. *J Cell Physiol*. 2004;204:106–12.
20. Geenen V, Defresne MP, Robert F, Legros JJ, Franchimont P, Boniver J. The neurohormonal thymic microenvironment: immunocytochemical evidence that thymic nurse cells are neuroendocrine cells. *Neuroendocrinology*. 1988;47:365–8.
21. Jessop DS, Chowdrey HS, Lightman SL, Larsen PJ. Vasopressin is located within lymphocytes in the rat spleen. *J Neuroimmunol*. 1995;56:219–23.
22. Friedmann AS, Memoli VA, North WG. Evidence for vasopressin production in the human gastrointestinal system. *Peptides*. 1991;12:1051–6.
23. Wathes DC, Swann RW, Hull MG, Drife JO, Porter DG, Pickering BT. Gonadal sources of the posterior pituitary hormones. *Prog Brain Res*. 1983; 60:513–9.
24. Nicholson HD, Swann RW, Burford GD, Wathes DC, Porter DG, Pickering BT. Identification of oxytocin and vasopressin in the testis and in adrenal tissue. *Regul Pept*. 1984;8:141–6.
25. Ivell R, Furuya K, Brackmann B, Dawood Y, Khan-Dawood F. Expression of the oxytocin and vasopressin genes in human and baboon gonadal tissues. *Endocrinology*. 1990;127:2990–6.
26. Assinder SJ, Carey M, Parkinson T, Nicholson HD. Oxytocin and vasopressin expression in the ovine testis and epididymis: changes with the onset of spermatogenesis. *Biol Reprod*. 2000;63:448–56.
27. Zhao JJ, Gjoerup OV, Subramanian RR, et al. Human mammary epithelial cell transformation through the activation of phosphatidylinositol 3-kinase. *Cancer Cell*. 2003;3:483–95.